

# **Ambiguous Genitalia**

**By**

**Dr David Segal**

**Paediatric Endocrinologist**

# What is the sex of the baby?

- **Genetic:** XX, XY or other
- **Gonadal:** Testes, ovaries, ovotestes, other
- **Phenotypic:** Male genitalia, female genitalia, ambiguous genitalia
- **Gender identity:** the gender felt by the individual to be most accurate
- **Gender role:** gender typical behaviours

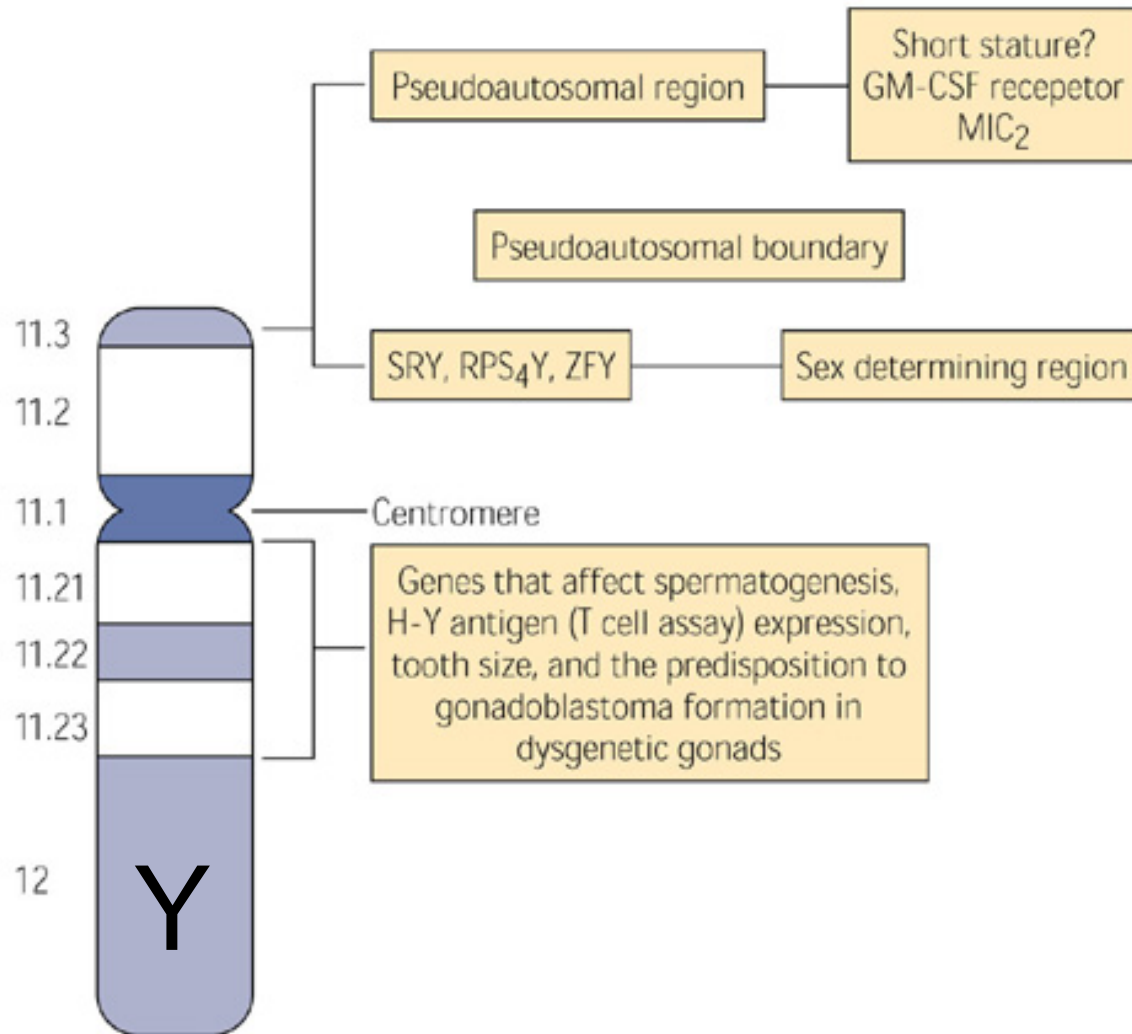
# **SEX Determination**

- Gonads**
- Internal genital structures**
- External genital structures**
- All develop from bi-potential embryonic tissues**

- Determination and differentiation depend on the **regulated expression** and **interaction** of specific **genes** and their **gene products**

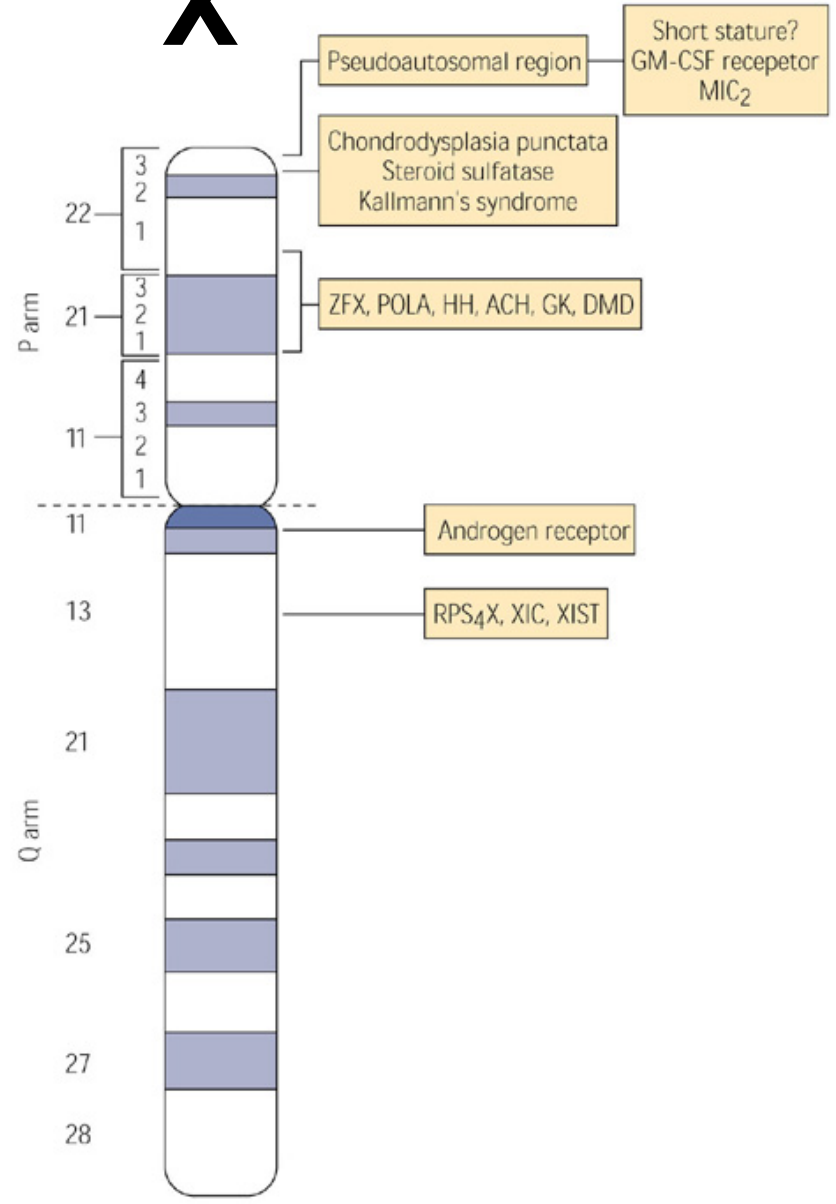
- Sex determination:
  - Sex chromosome to gonadal differentiation
  - Sex determination sets the stage for sex differentiation
- Sex differentiation:
  - Sex-specific response of tissues to hormones produced by the gonads

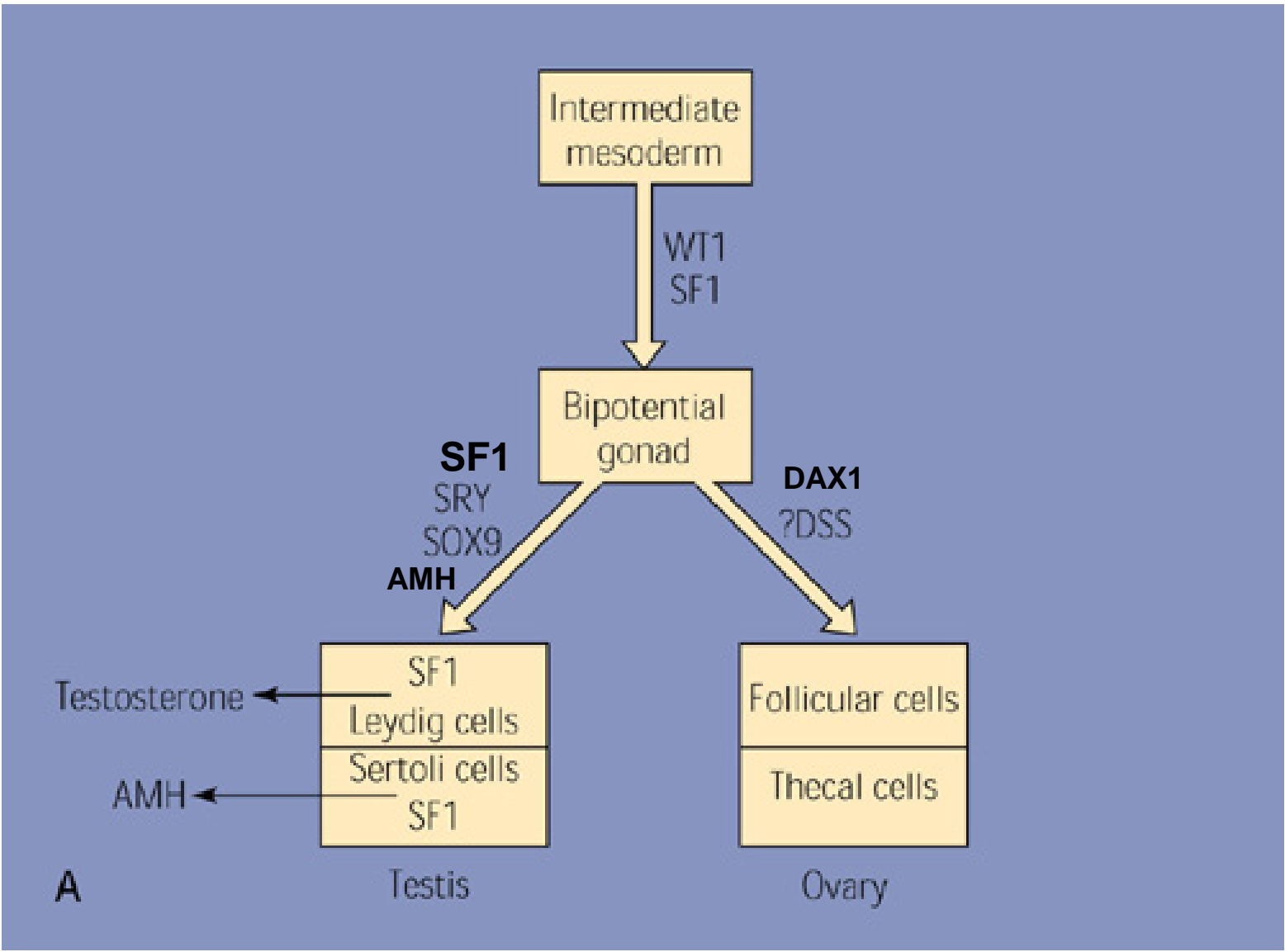
# The Players





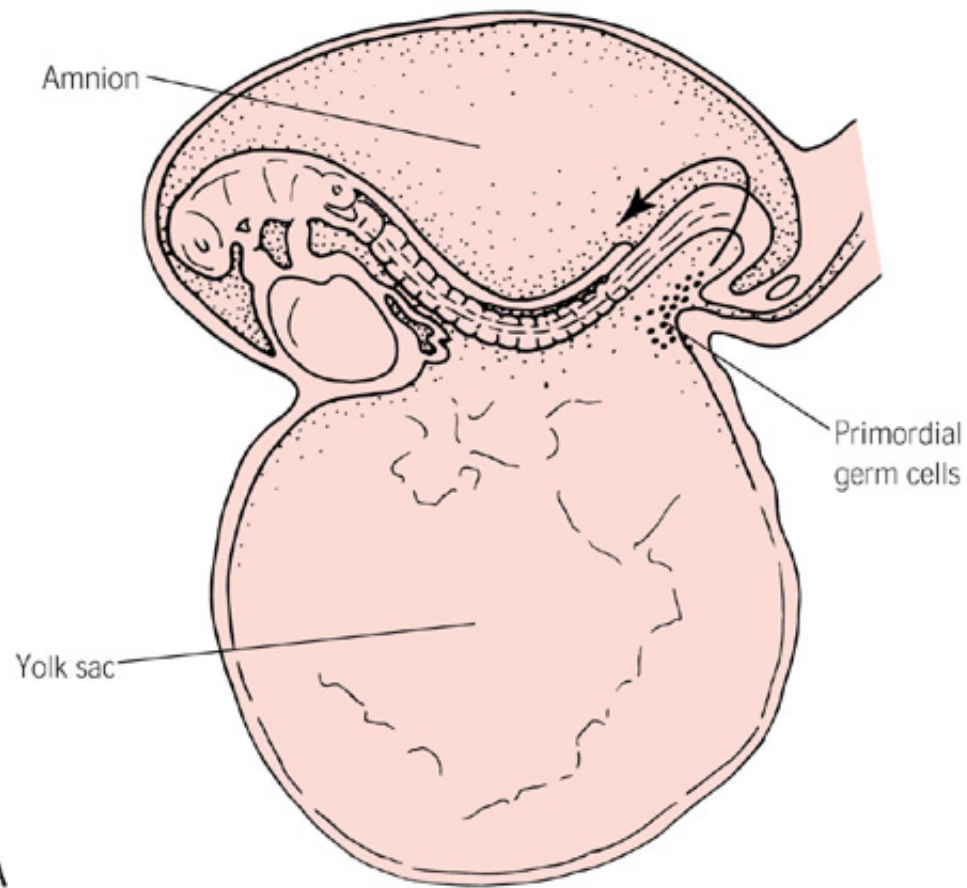
# X



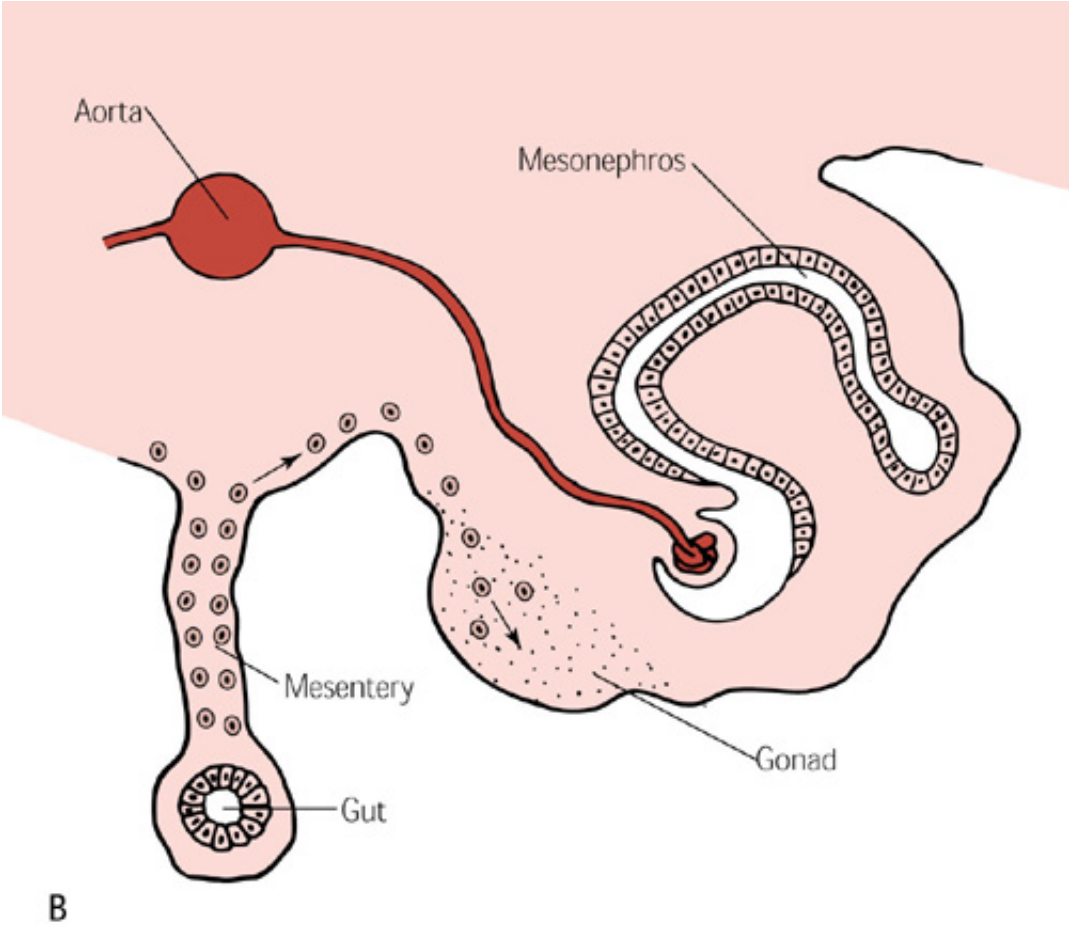




# Primordial germ cells

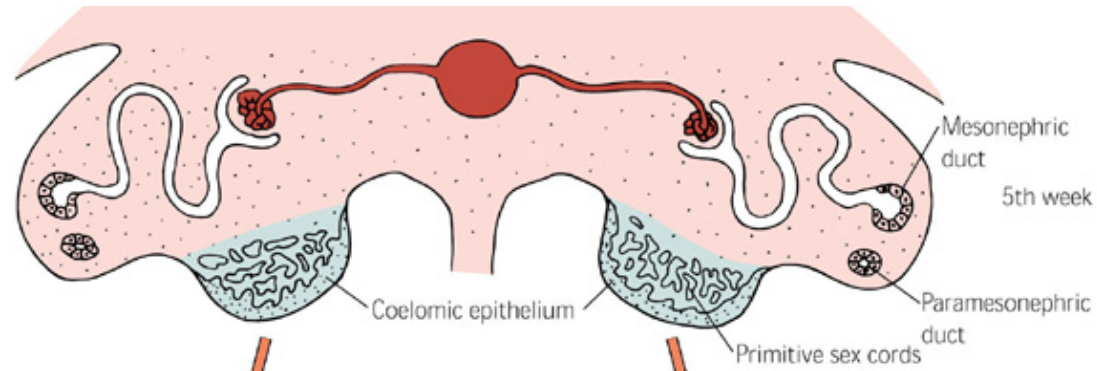


# Primordial germ cells

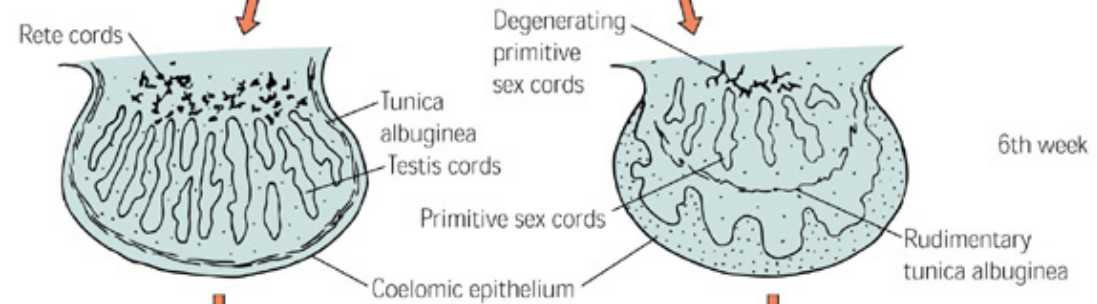


# Gonadal differentiation

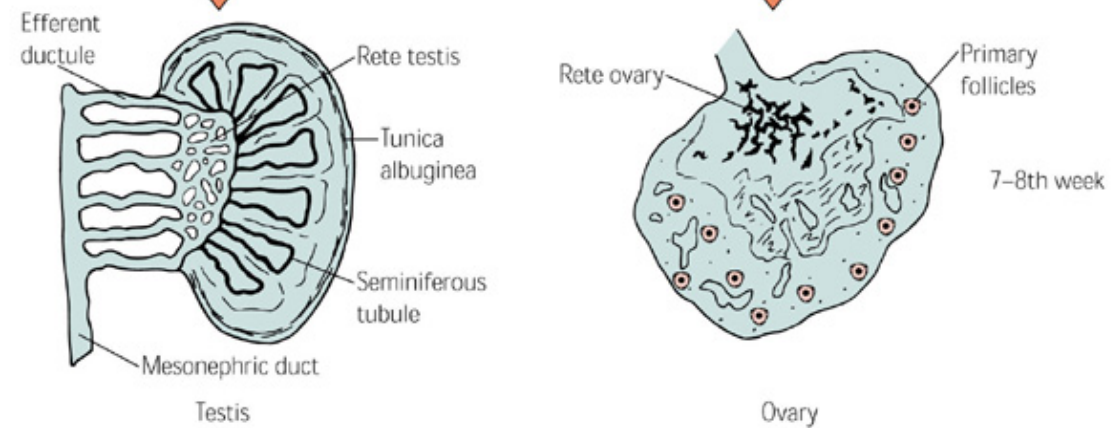
4-6 WEEKS

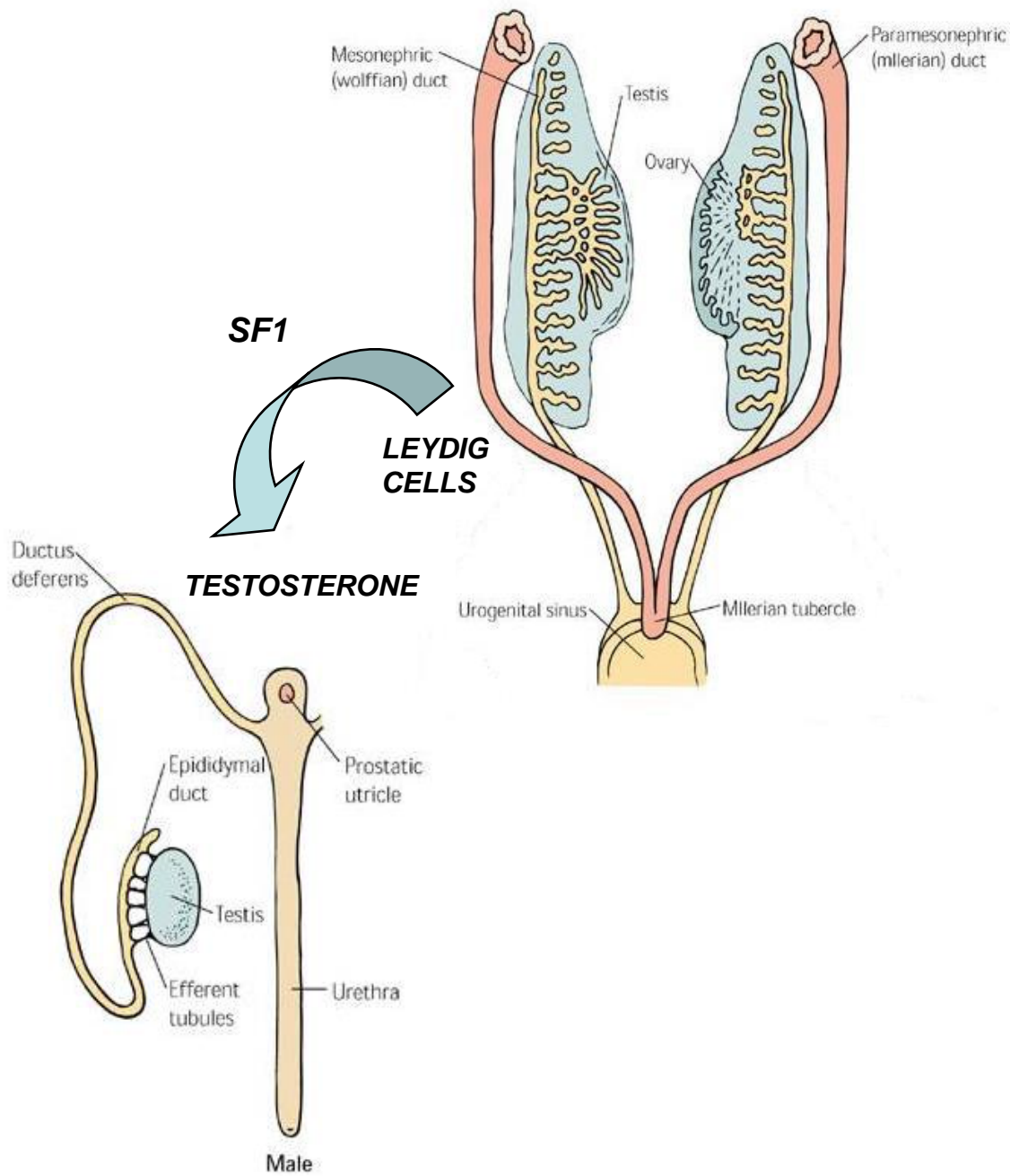


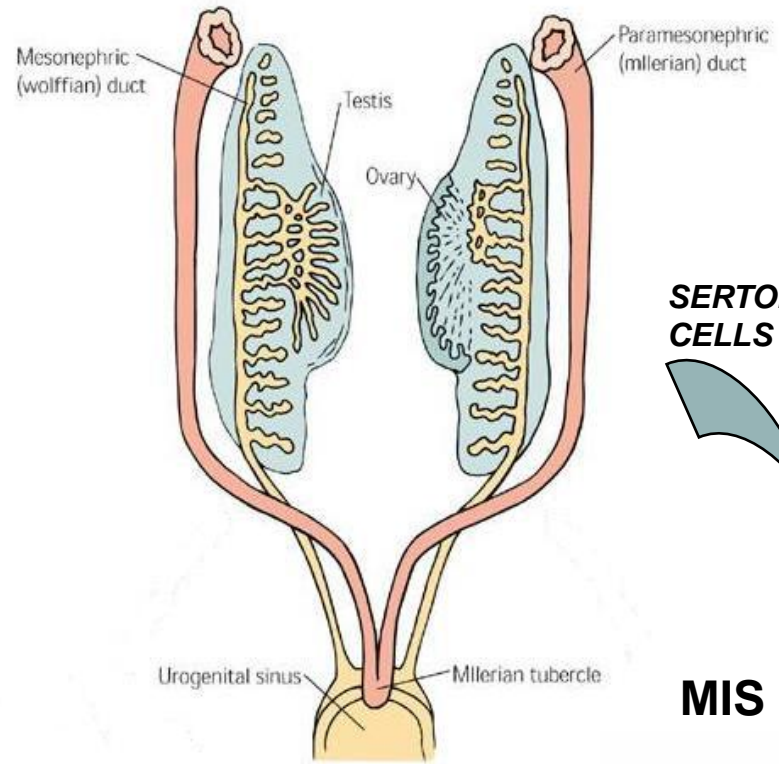
6-7 WEEKS



**3 CELL TYPES**  
**SUPPORTING**  
**STEROIDOGENIC**  
**GERM**



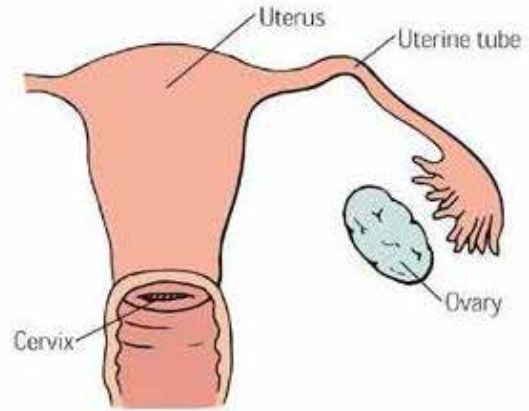




**SERTOLI  
CELLS**

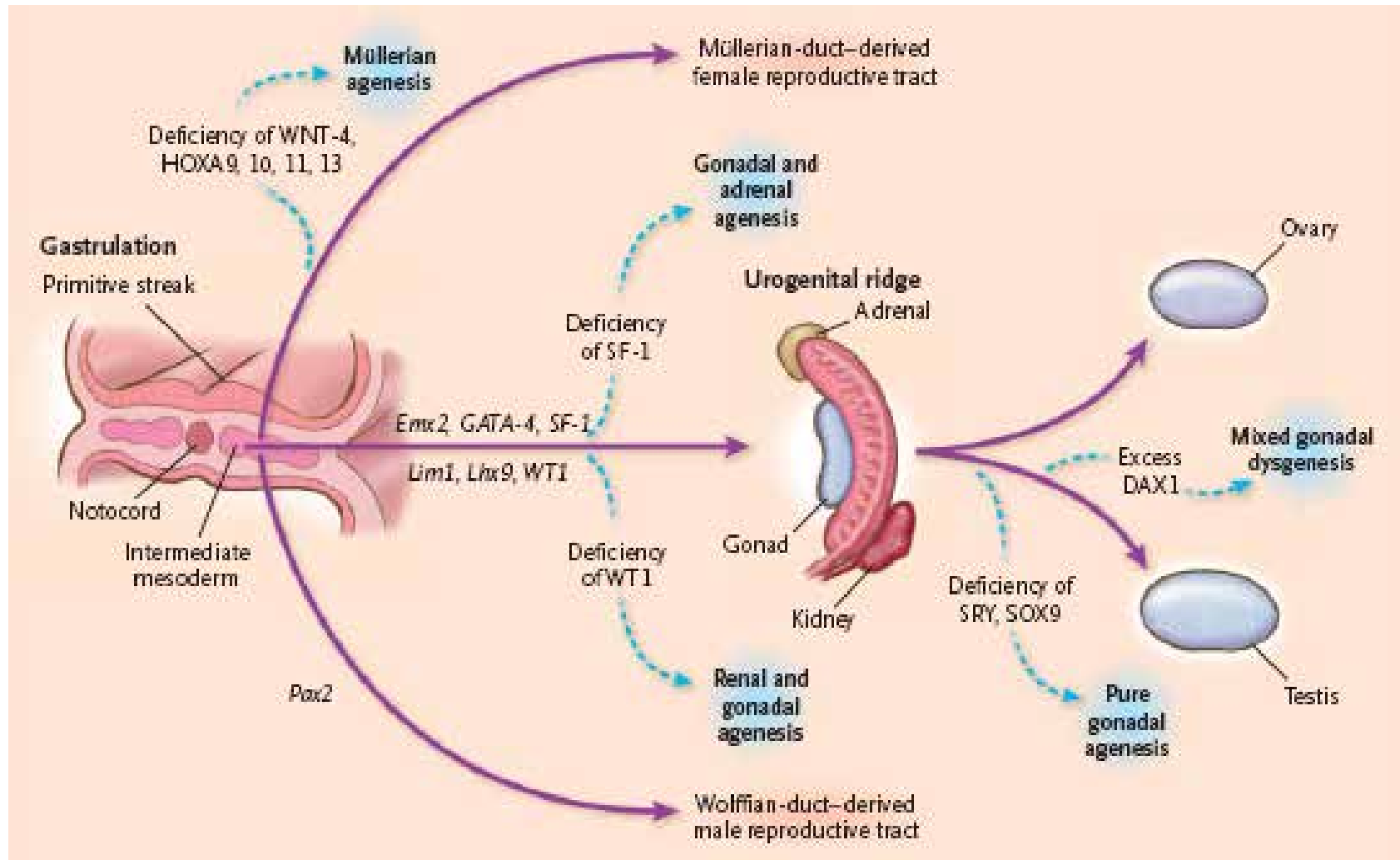
**WT1  
SF1**

**MIS**

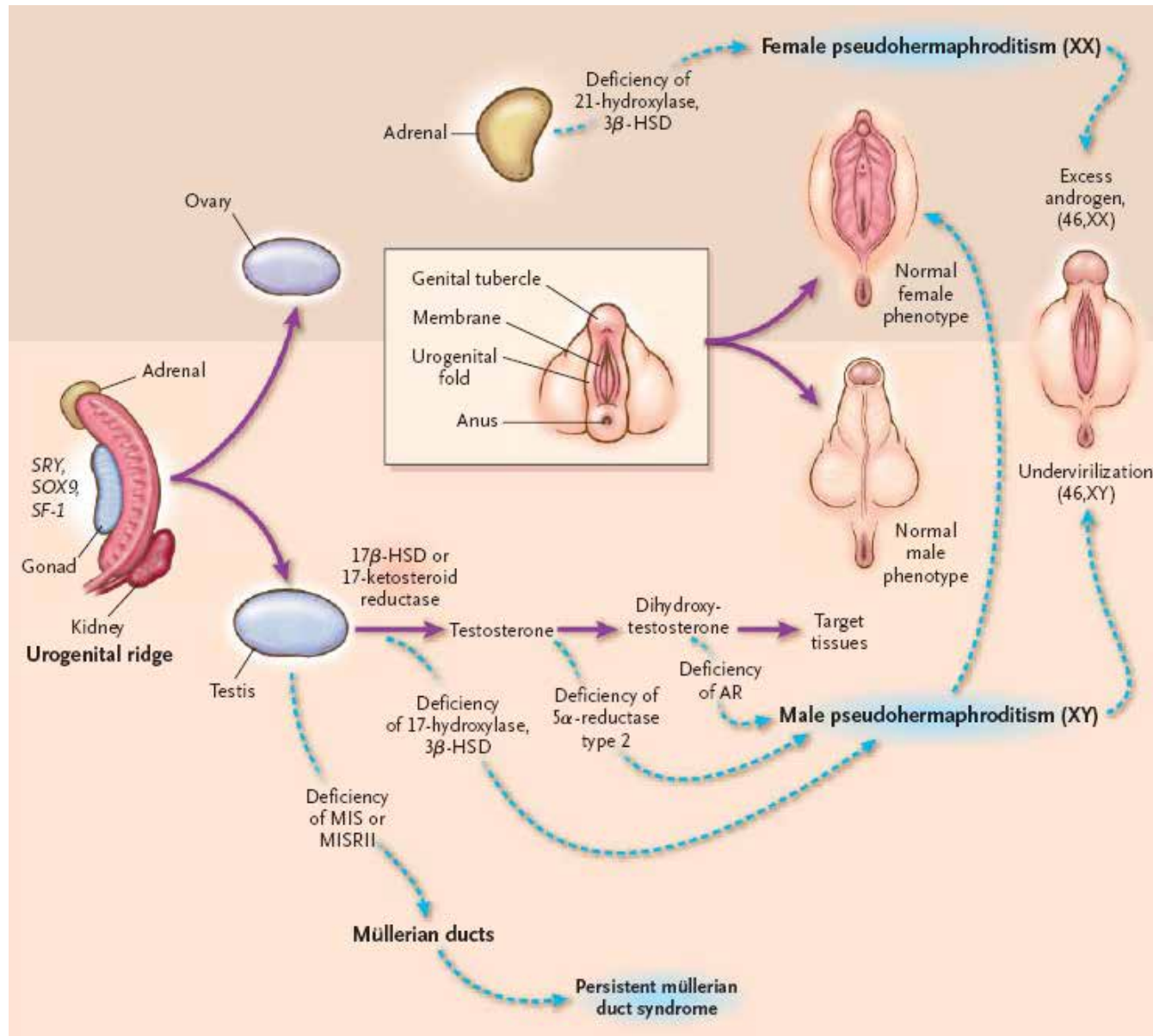


Female

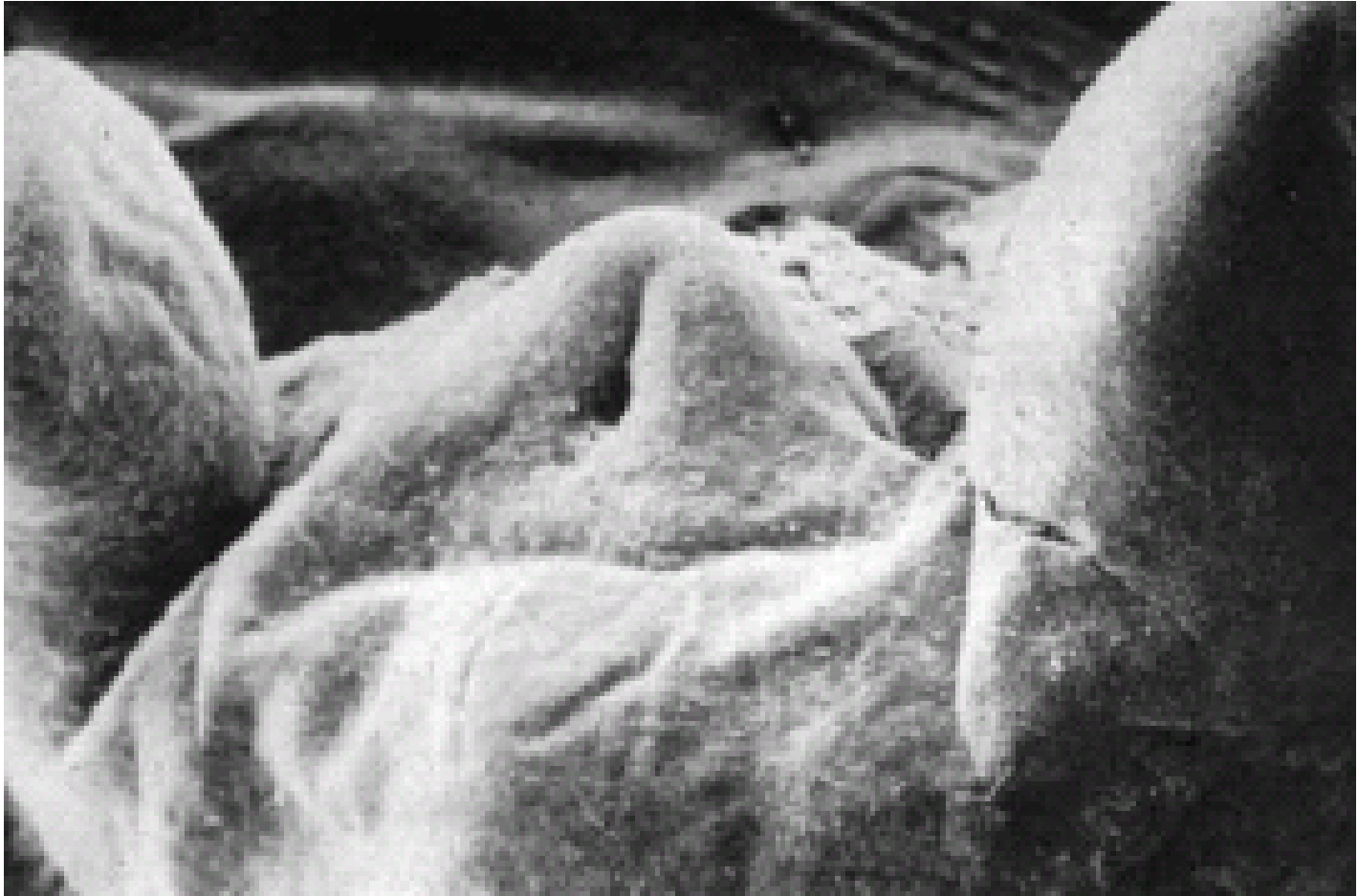# Syndromes of Dysgenesis during the Development of the Urogenital Ridge.



# Disorders of Differentiation

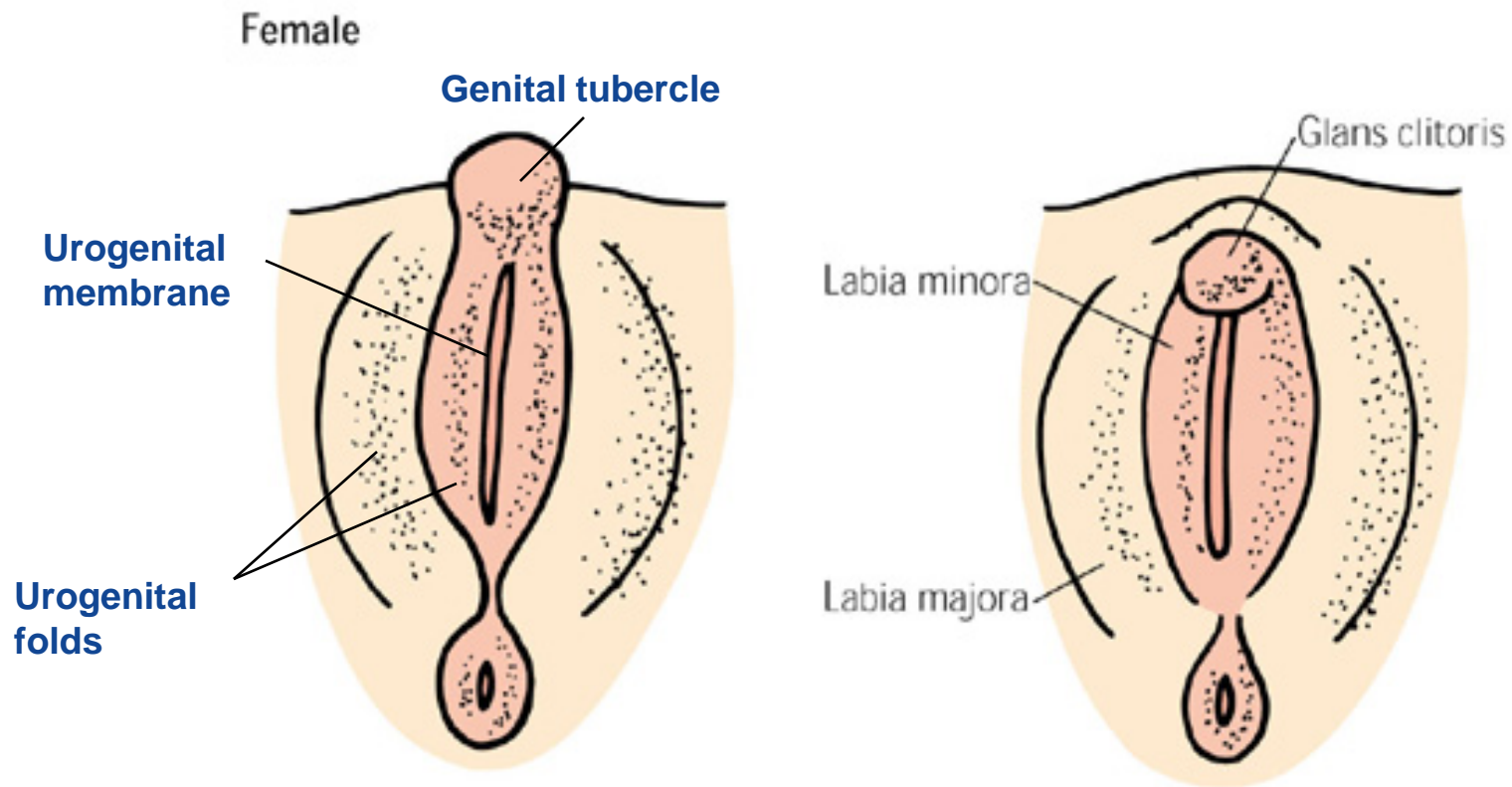


# Genitalia 7 weeks Indifferent stage

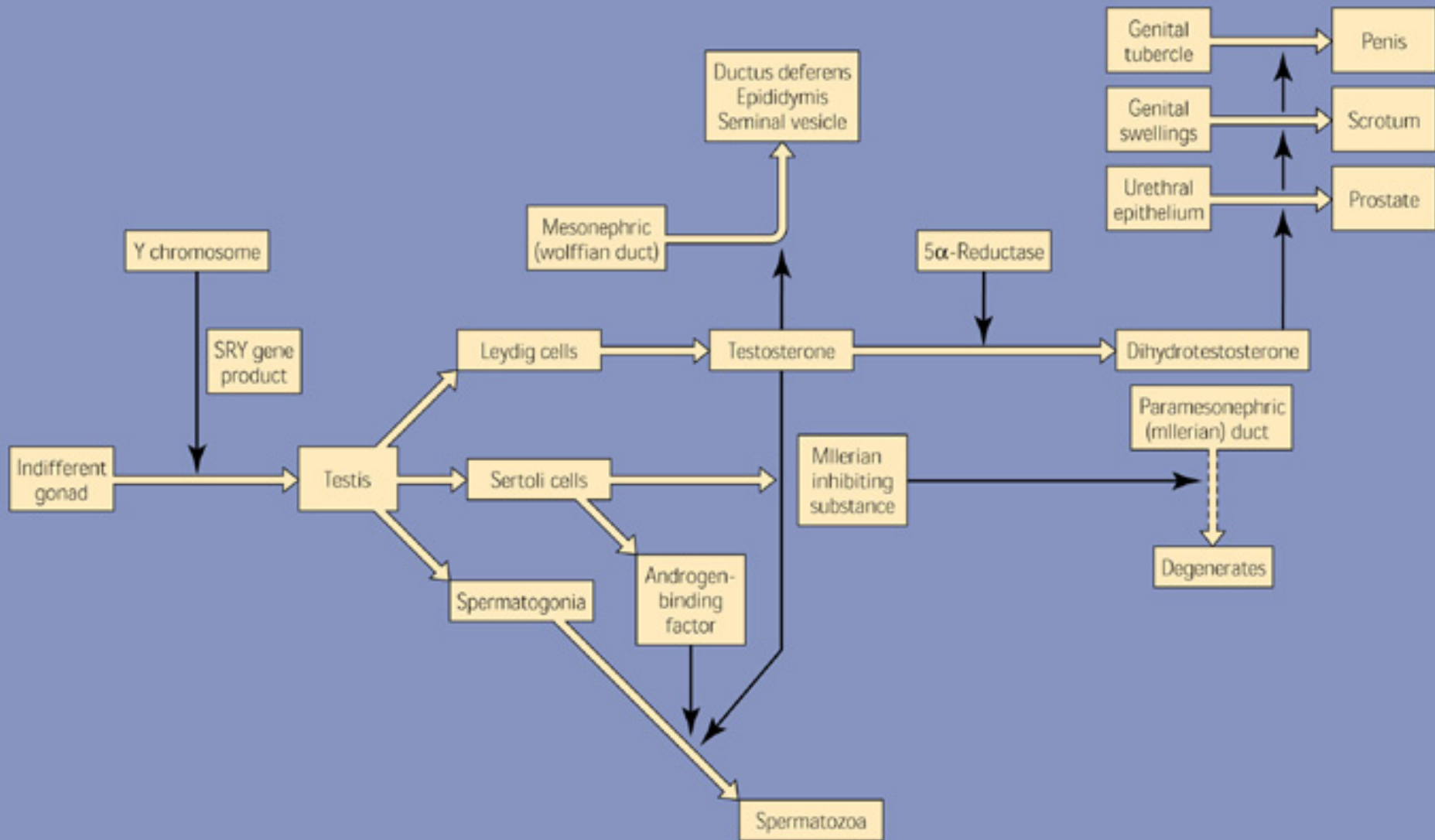




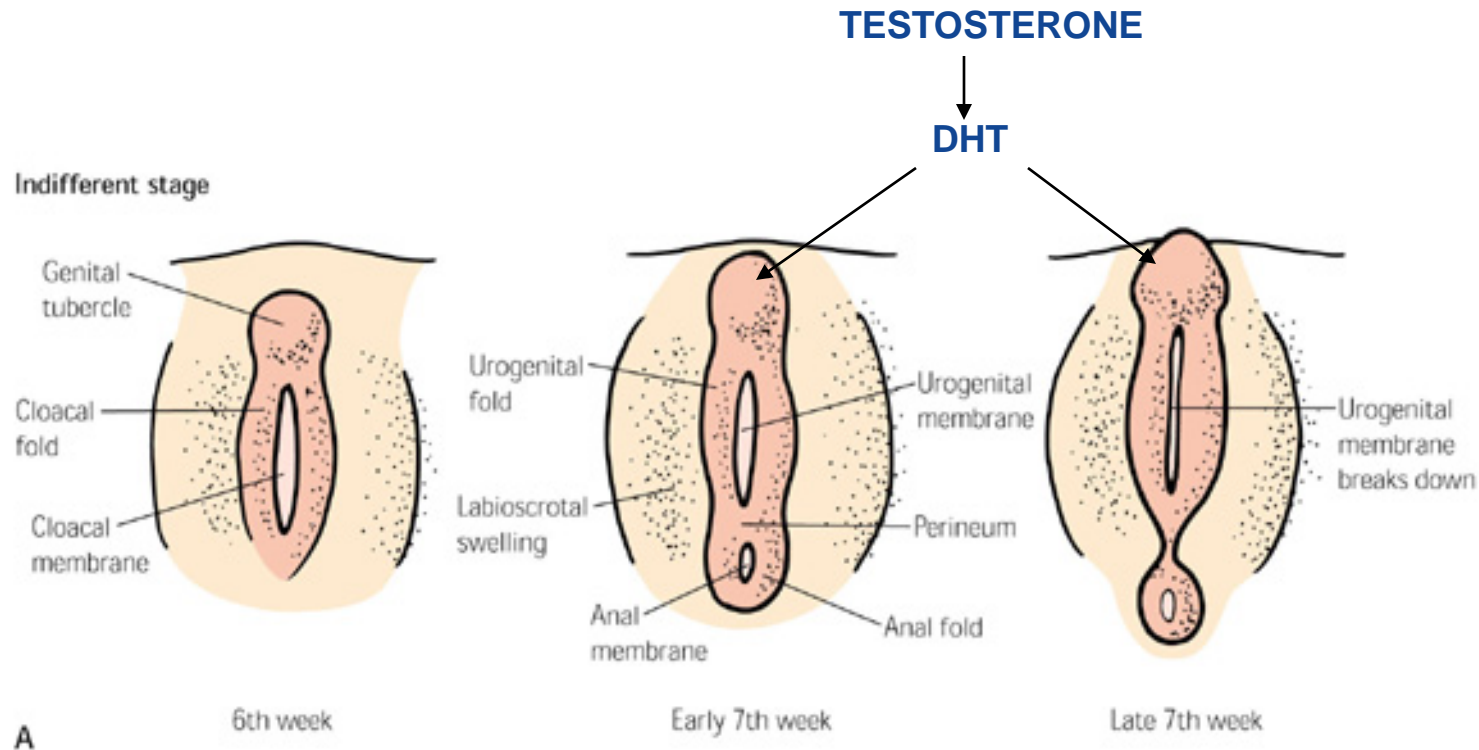
# Female external genitalia development



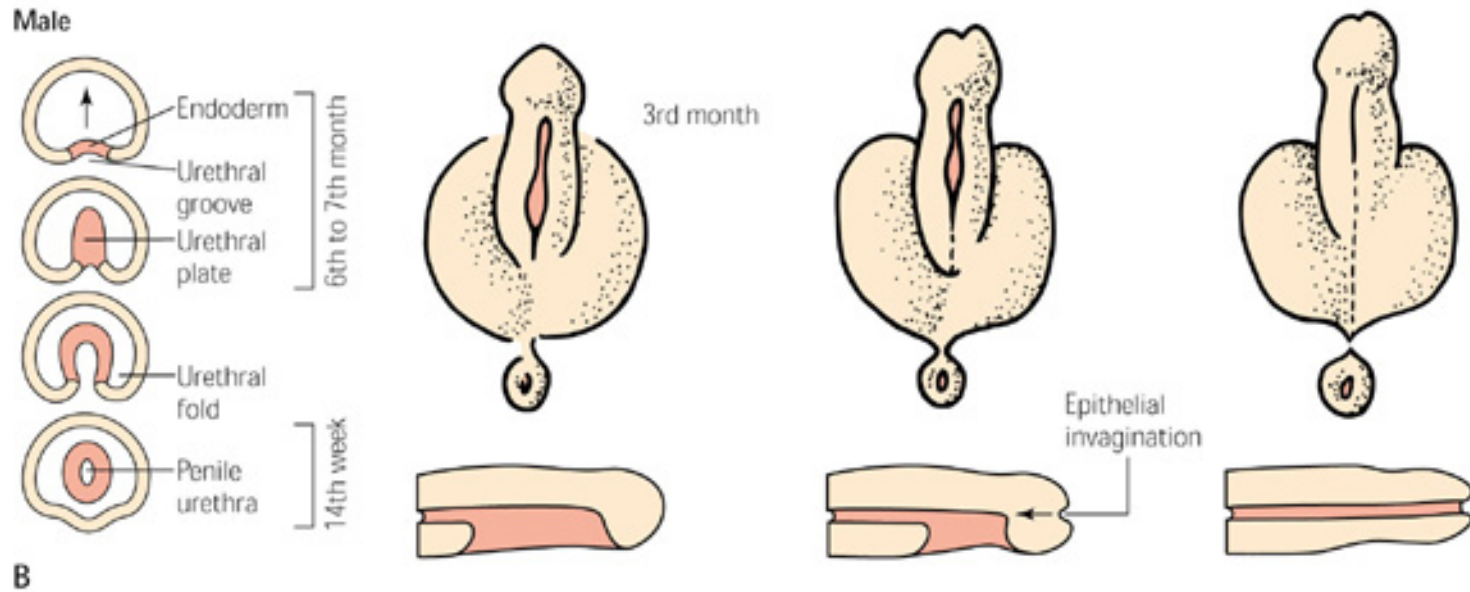
# Male sexual differentiation



# Development of male external genitalia



# Development of male external genitalia



# Classification of Genital Ambiguity

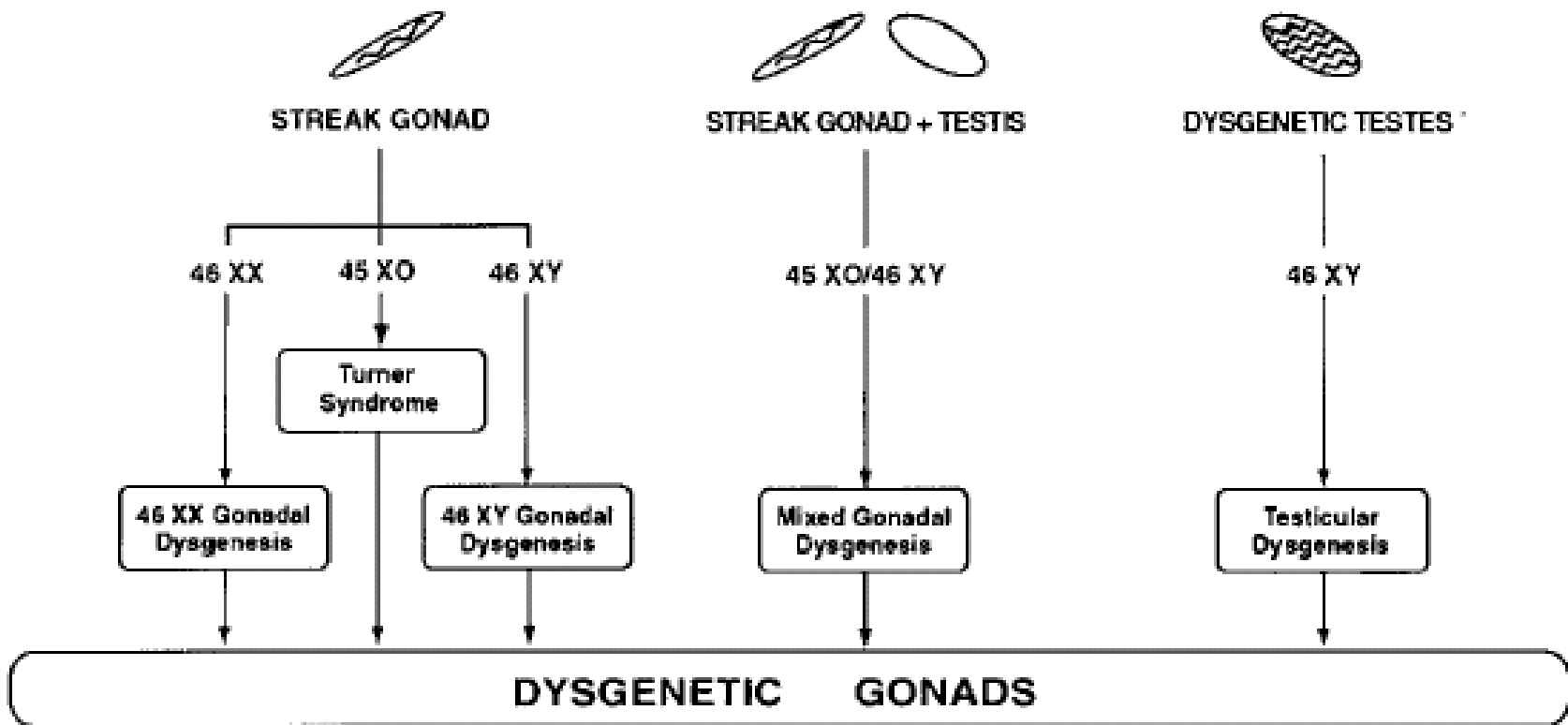
```
graph TD; A[Classification of Genital Ambiguity] --> B[Gonadal Dysgenesis]; A --> C[True Hermaphrodite]; A --> D[Under-virilized Male]; A --> E[Virilized Female];
```

**Gonadal  
Dysgenesis**

**True  
Hermaphrodite**

**Under-virilized  
Male**




**Virilized  
Female**



# Classification of Genital Ambiguity

**Gonadal  
Dysgenesis**

**Pure Gonadal Dysgenesis  
Partial Testicular Dysgenesis  
Mixed Gonadal Dysgenesis**

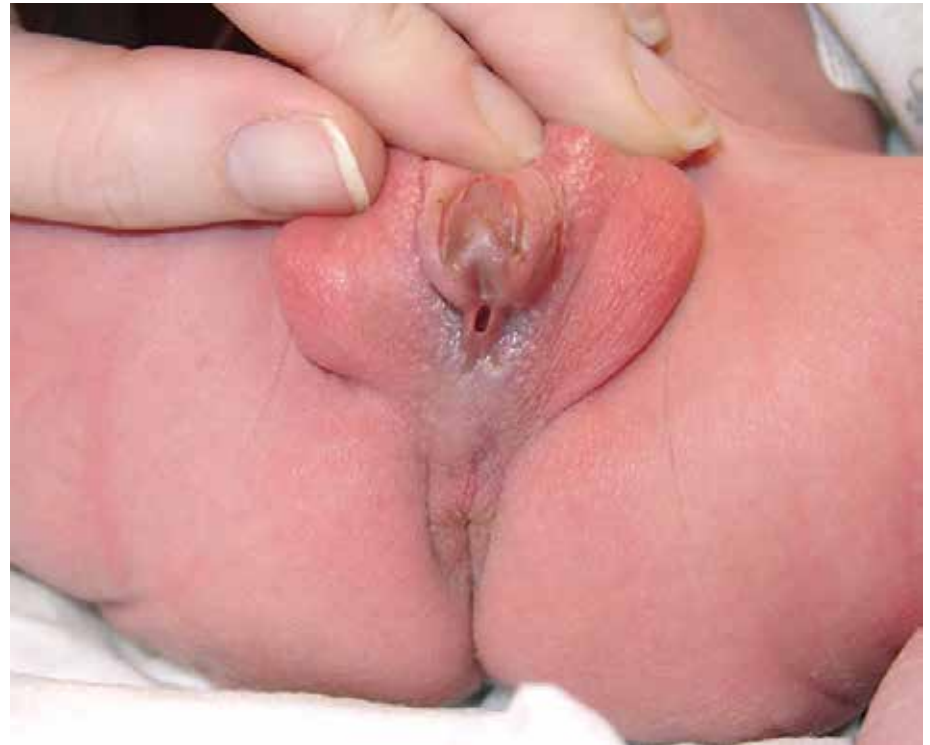
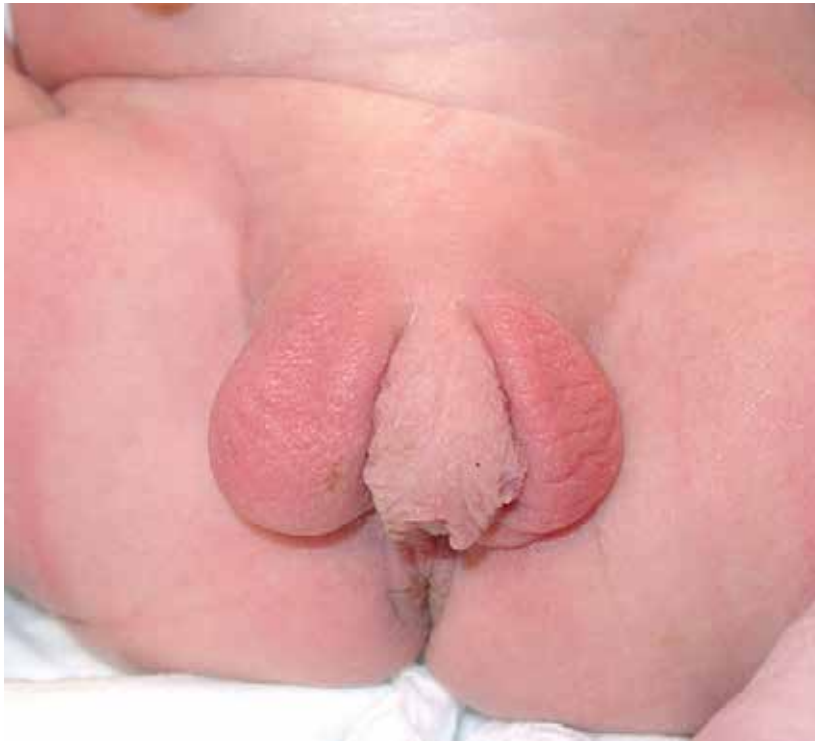
# Gonadal dysgenesis

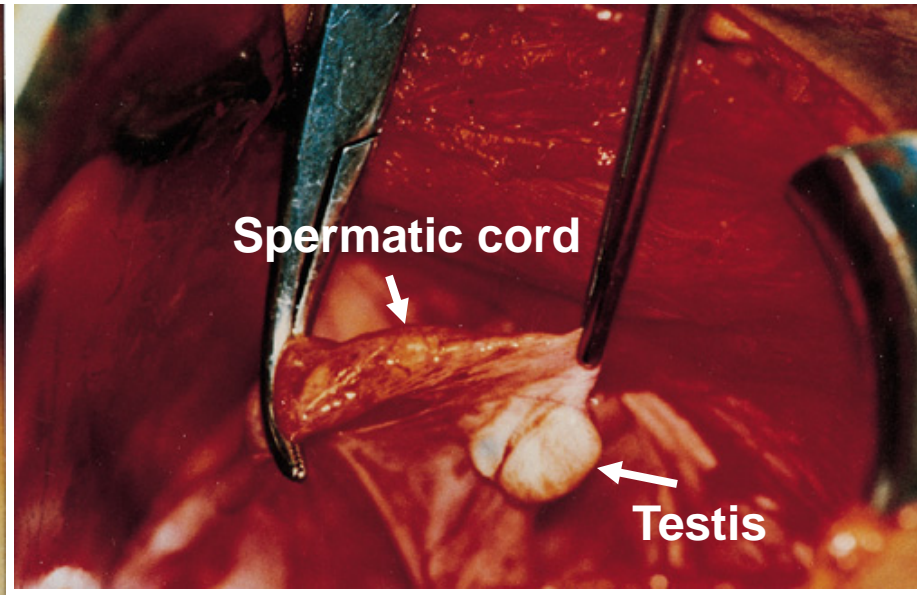
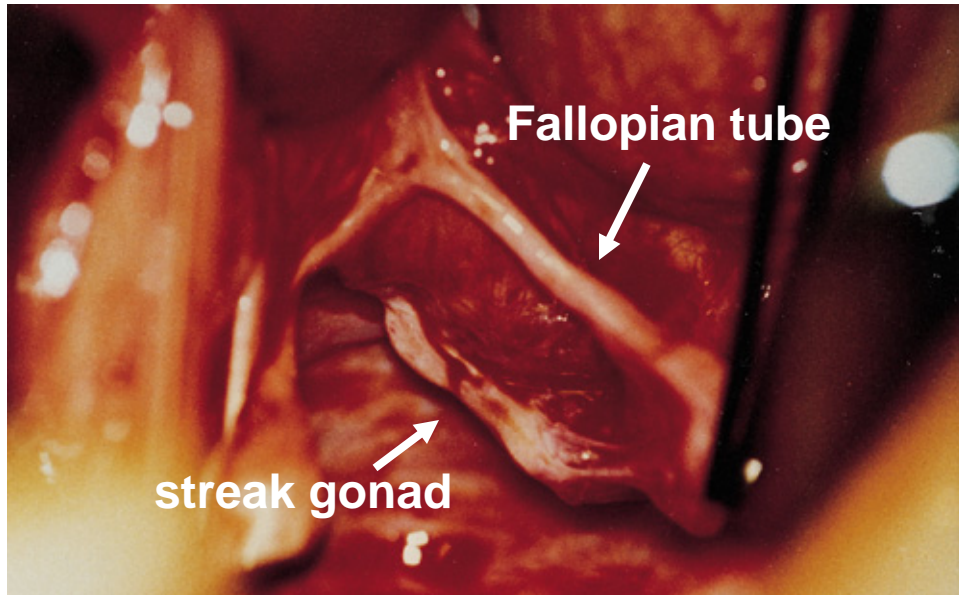
- **Spectrum of disorders leading to maldevelopment of the gonads**
  - **46XY pure gonadal dysgenesis**
  - **Multiple cell lines including a monosomy X mixed gonadal dysgenesis-most often 45,X/46,XY**
  - **True hermaphrodite often 46,XX/46,XY**
  - **46,XX males, 46,XY females**



# **XO/XY/XXY mixed/asymmetric gonadal dysgenesis**



**16y old female, short stature and sexual infantilism  
46,XY asymmetric gonadal dysgenesis**



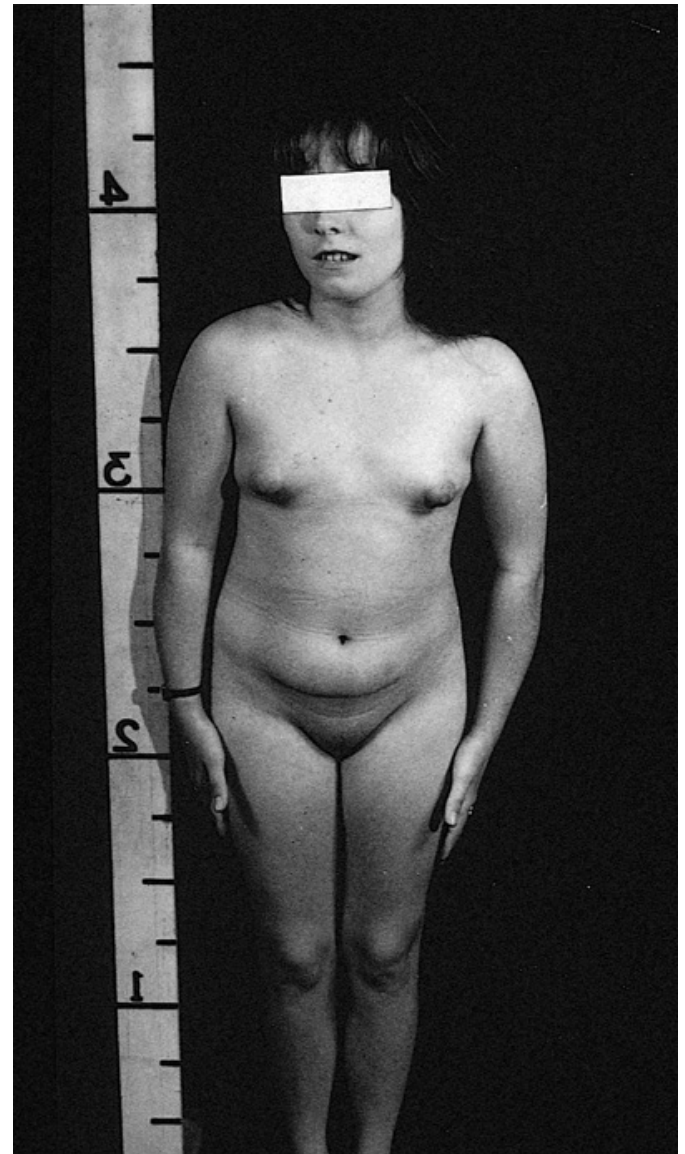
# Pure gonadal dysgenesis

14y old female

45,X/46,XY

Short stature

Bilateral streak gonads



# Deletion syndrome 45,X/46,XY

**A 15-year-old female**

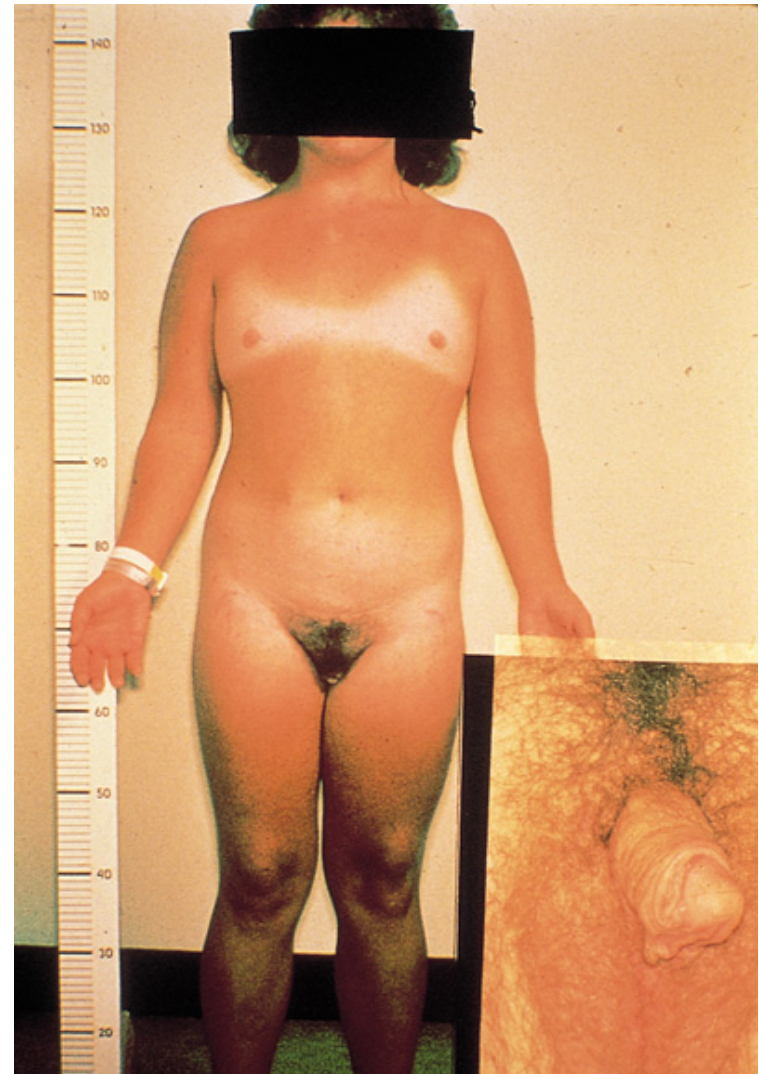**45,X/46,X,idic(Y)/47,XY,+idic(Y)**

**Short stature**

**Clitoromegaly**

**Right streak gonad**

**Left immature testis.**



**2-mo old female**

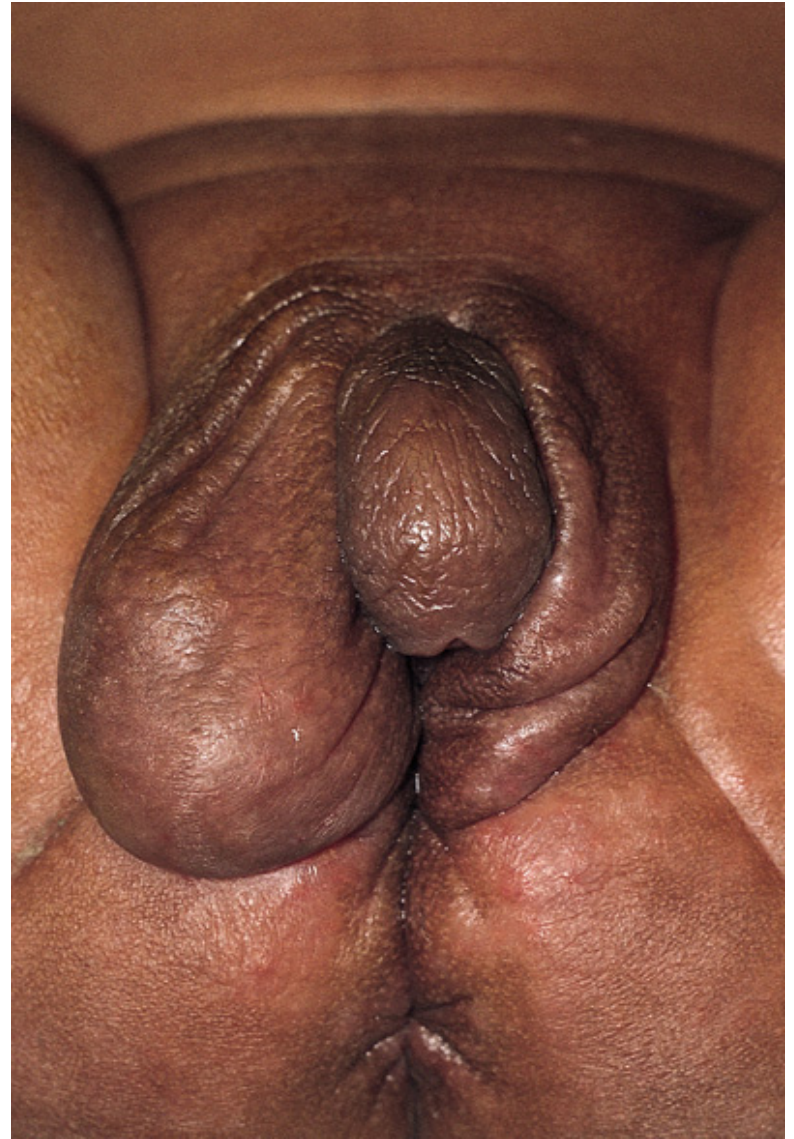**45,X/46,XY**

**Frank sexual ambiguity**

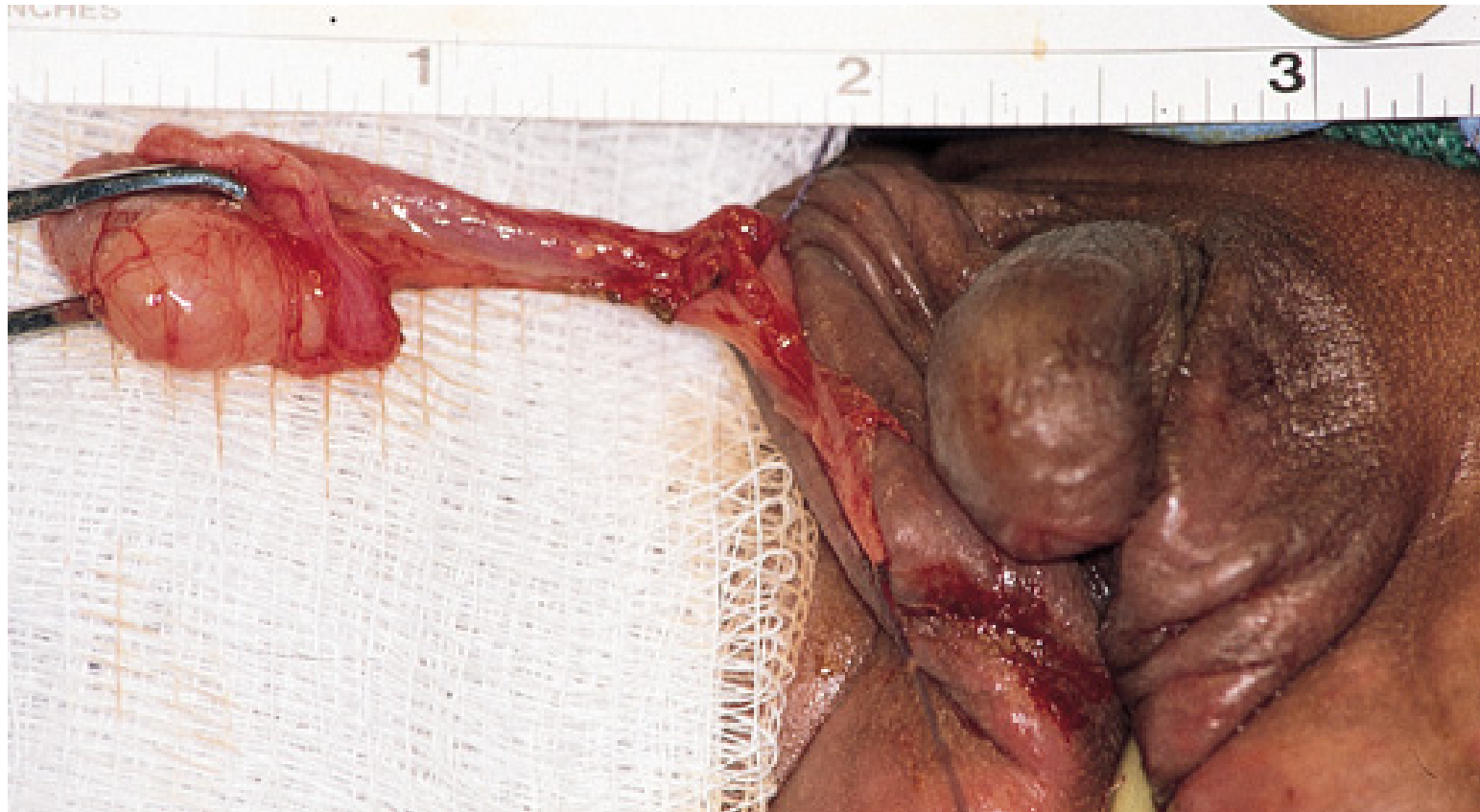
**Clitoromegaly**

**Right scrotal gonad**

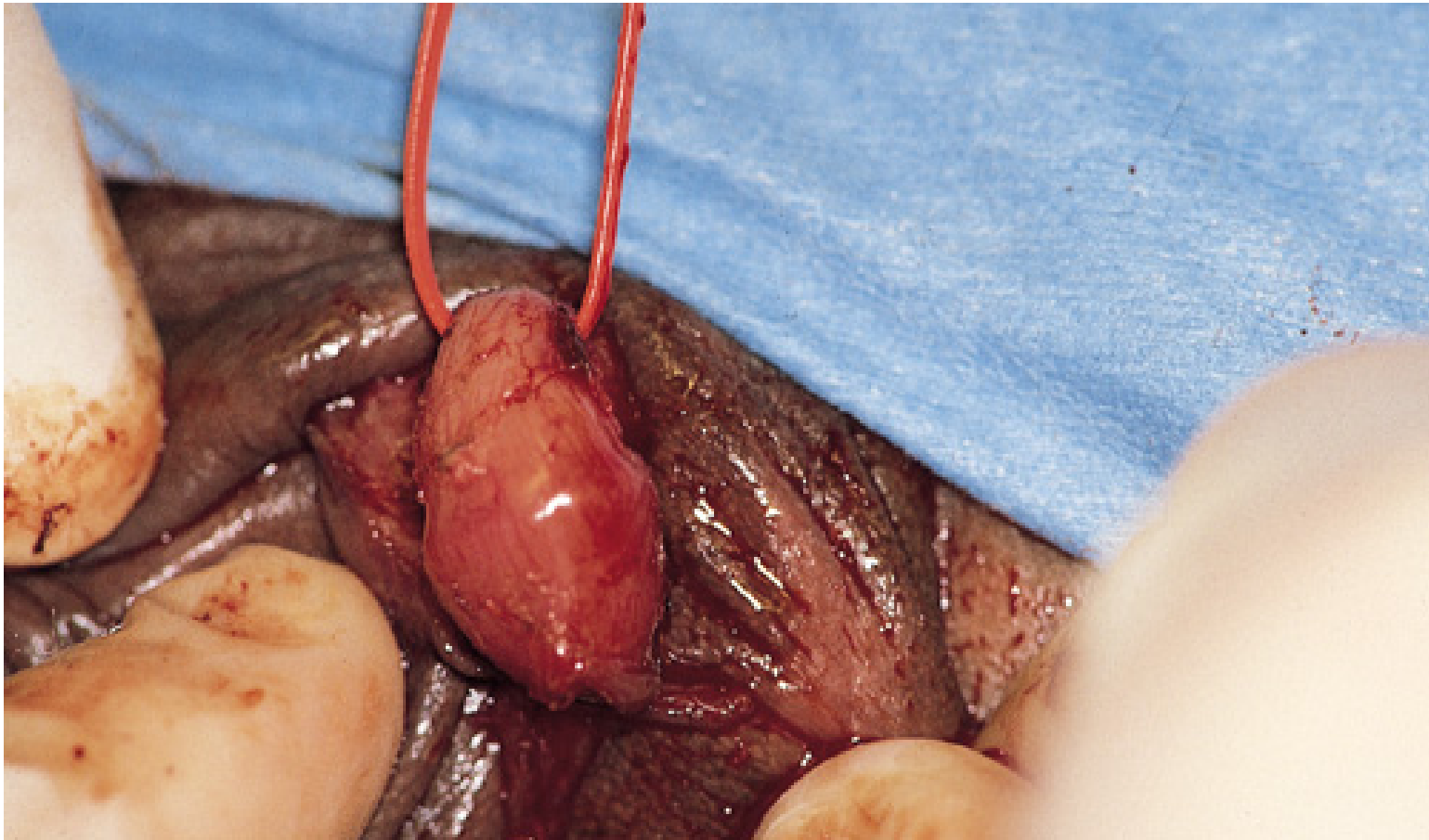**Empty left labioscrotal pouch**



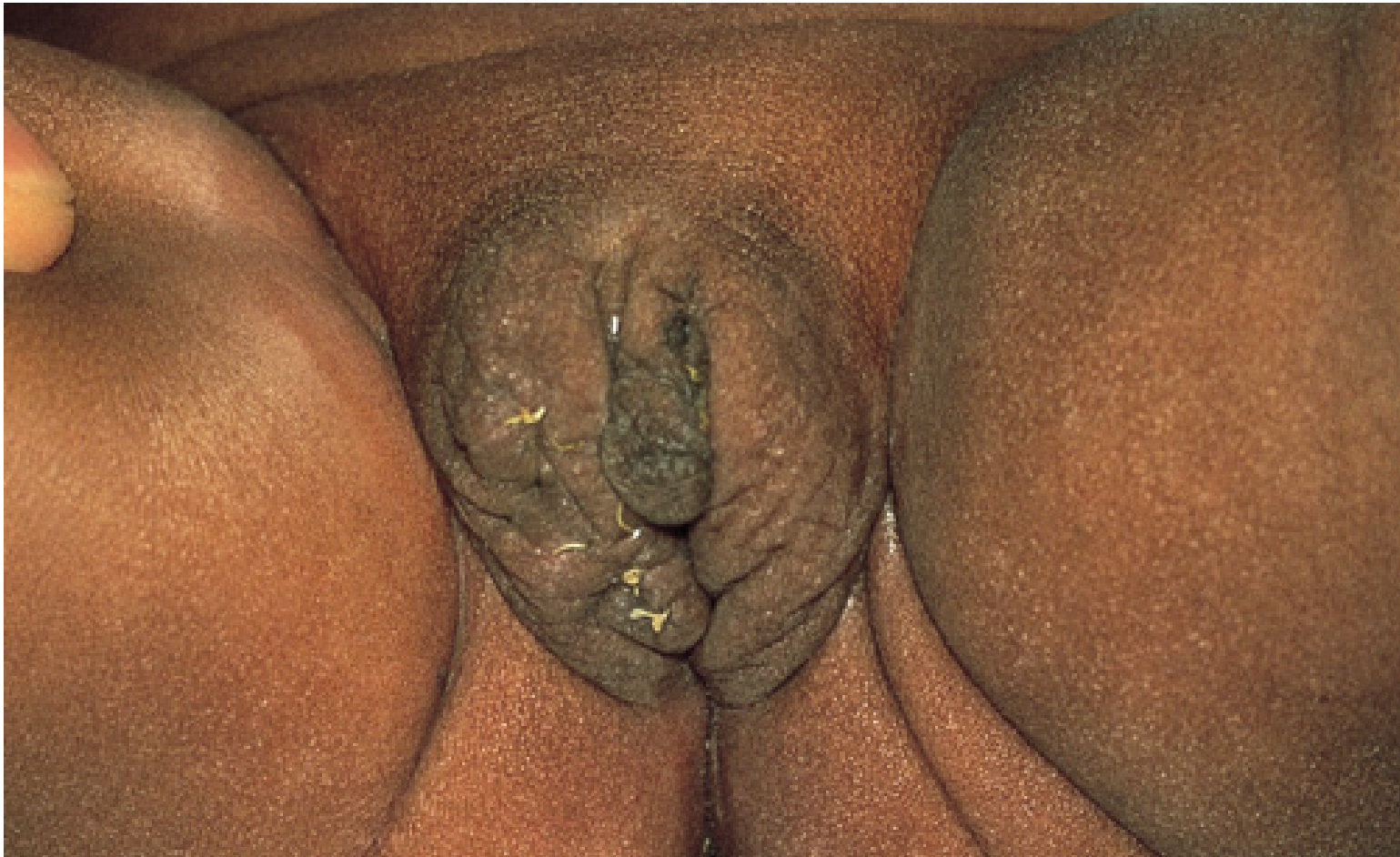## Gonadectomy and reduction clitoroplasty



## Gonadectomy and reduction clitoroplasty



## Gonadectomy and reduction clitoroplasty





# 46,XY Gonadal dysgenesis

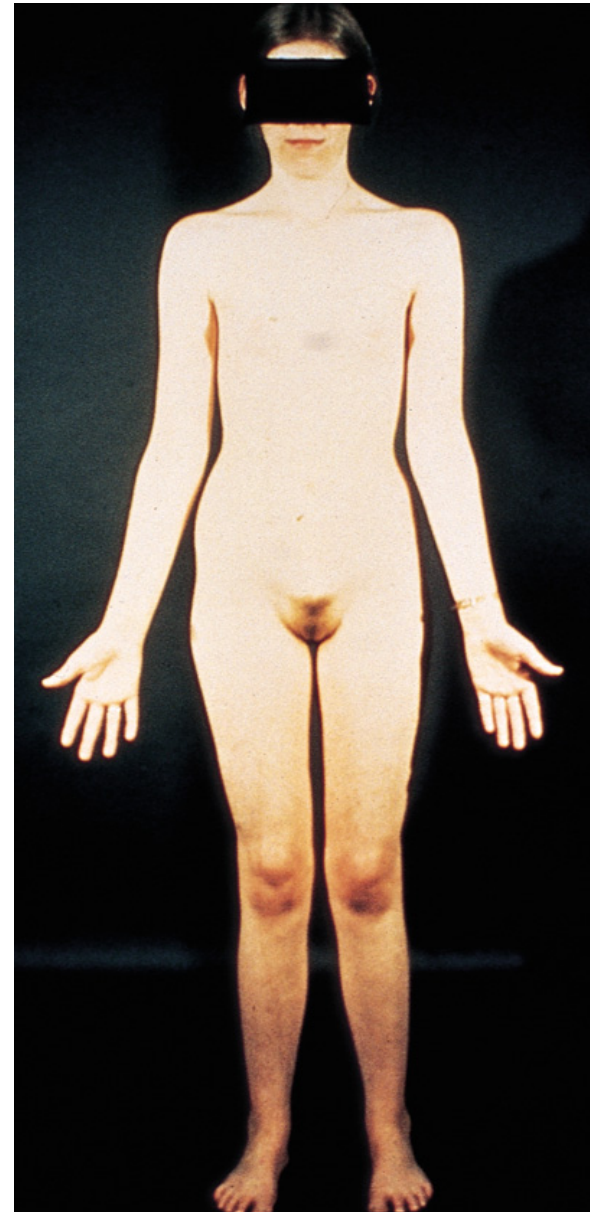
19-y old female

46,XY

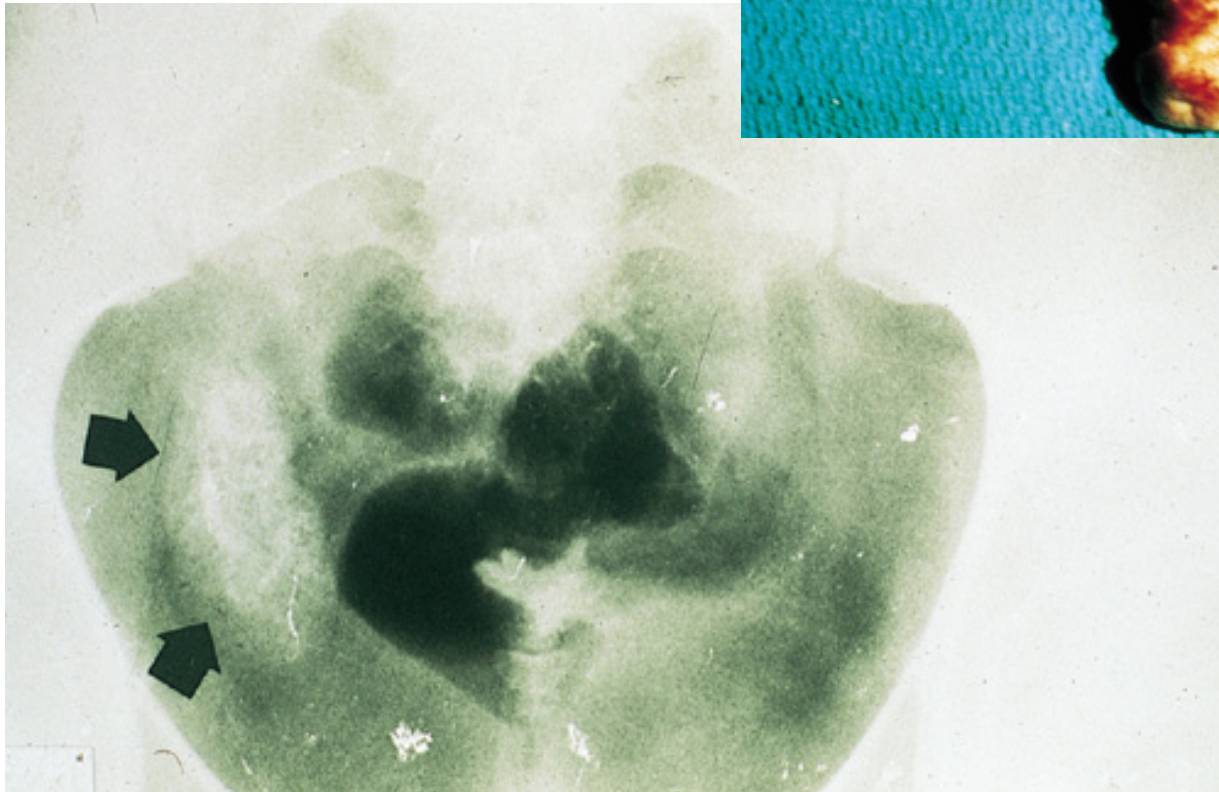
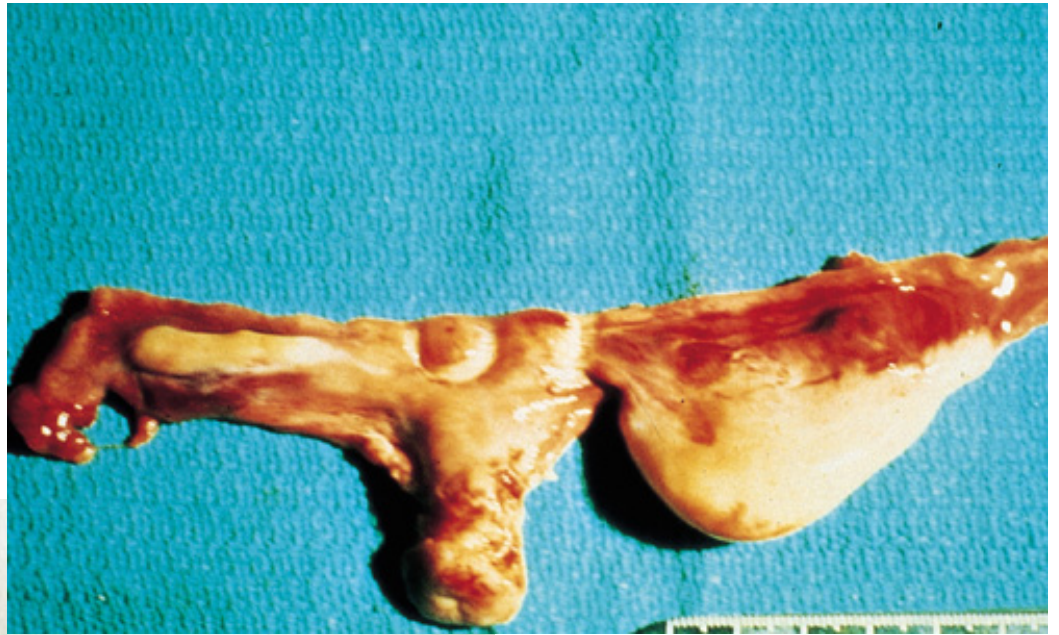Normal stature

Sexual infantilism

Endocrine profile of  
primary gonadal failure



**46,XY gonadal dysgenesis  
with calcified gonoblastoma**



# Salient features of the empty pelvis/agonadia/vanishing testes syndrome

## C. Salient Features of the Empty Pelvis/Agonadia/Vanishing Testes Syndrome

Karyotype:	46, XY			
Inheritance:	Sporadic; possibly autosomal recessive in familial cases			
Gonads:	Absent (CT, laparoscopy)			
Habitus:	Sexual infantilism at puberty			
Hormone profile:	? plasma FSH and LH, and minimal testosterone			
	<b>Testicular Regression Before 8 Weeks</b>	<b>Testicular Regression Between 8 and 10 Weeks</b>	<b>Testicular Regression After 12 to 14 Weeks</b>	<b>Incomplete Regression After 12 to 14 Weeks</b>
Genitalia	Female	Ambiguous	Male	Micropenis
Wolffian duct derivatives	Absent	Complete absence to partial development	Present	Present
Müllerian duct derivatives	Female	Complete absence to partial development	Absent	Absent
Gonads	Absent	Absent	Absent	Rudimentary testes

# Classification of Genital Ambiguity

```
graph TD; A[Classification of Genital Ambiguity] --> B[Gonadal Dysgenesis]; A --> C[True Hermaphrodite]; A --> D[Under-virilized Male]; A --> E[Virilized Female];
```

**Gonadal  
Dysgenesis**

**True  
Hermaphrodite**

**Under-virilized  
Male**

**Virilized  
Female**



**OVARY & TESTIS**

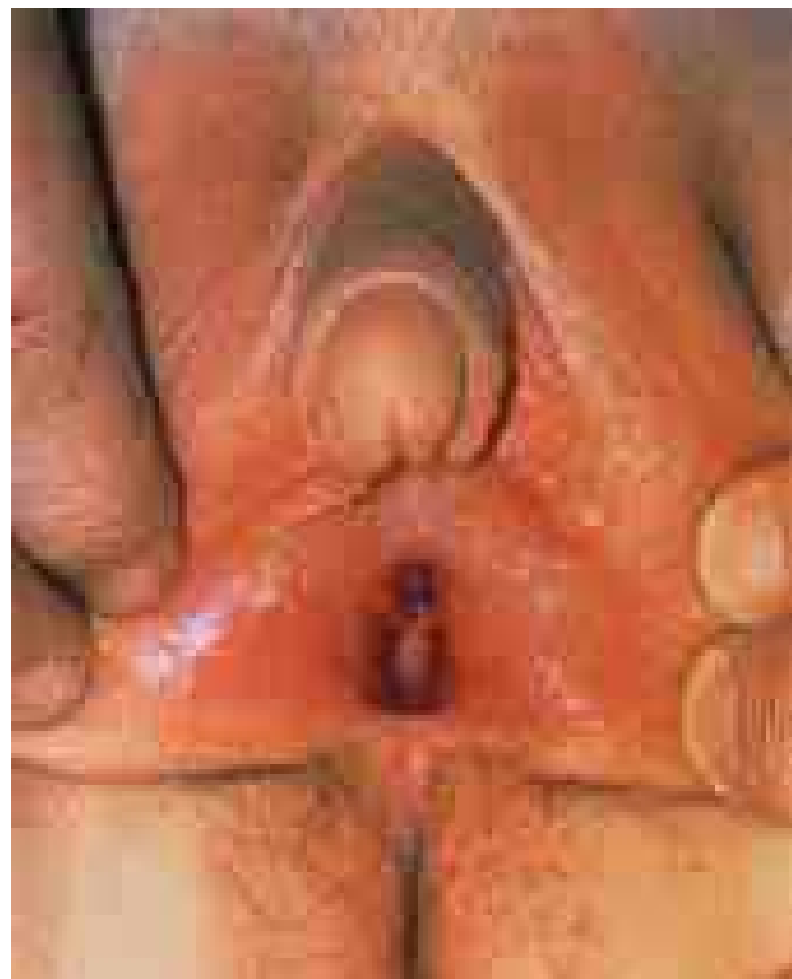
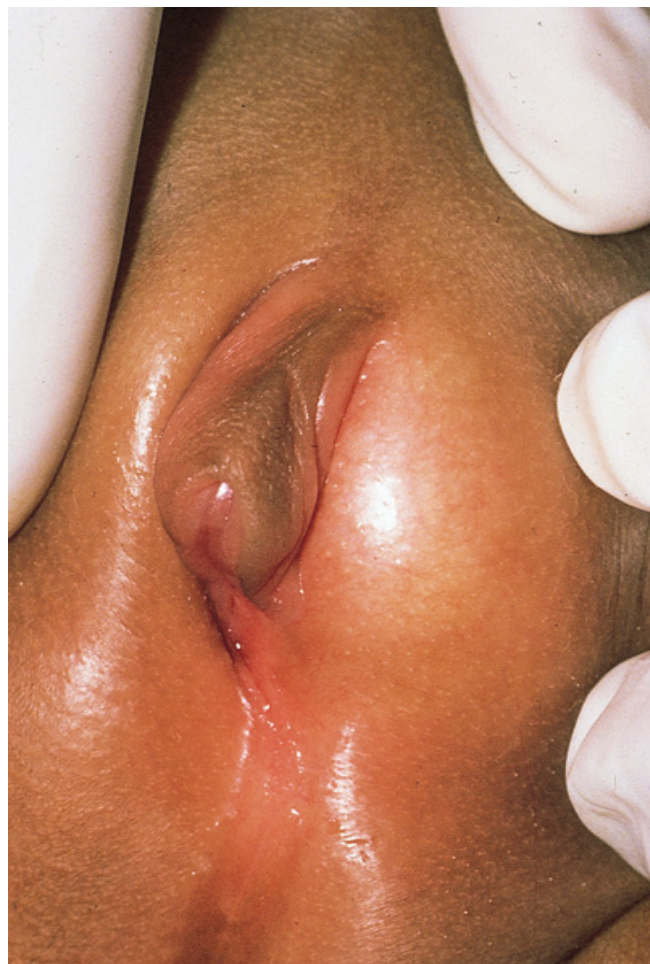
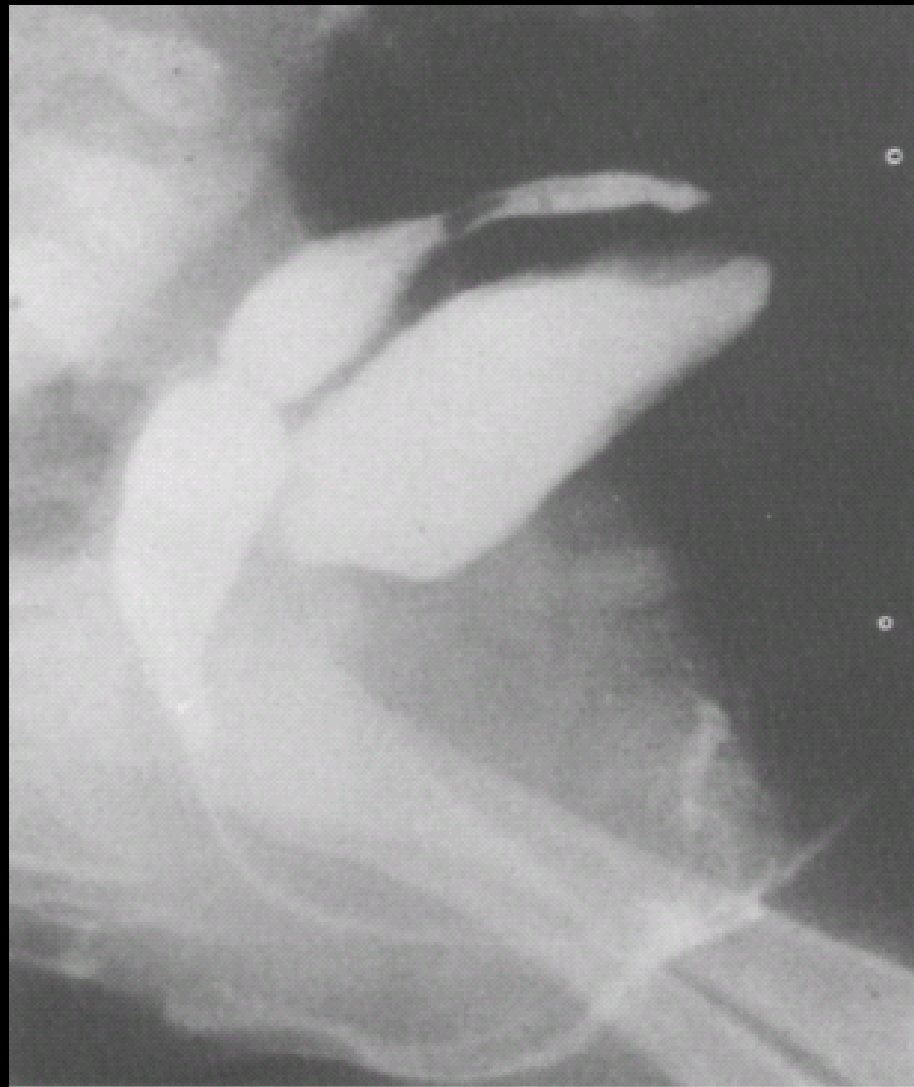**46 XX, 46 XY  
46 XX/XY etc.**



**TRUE HERMAPHRODITISM**

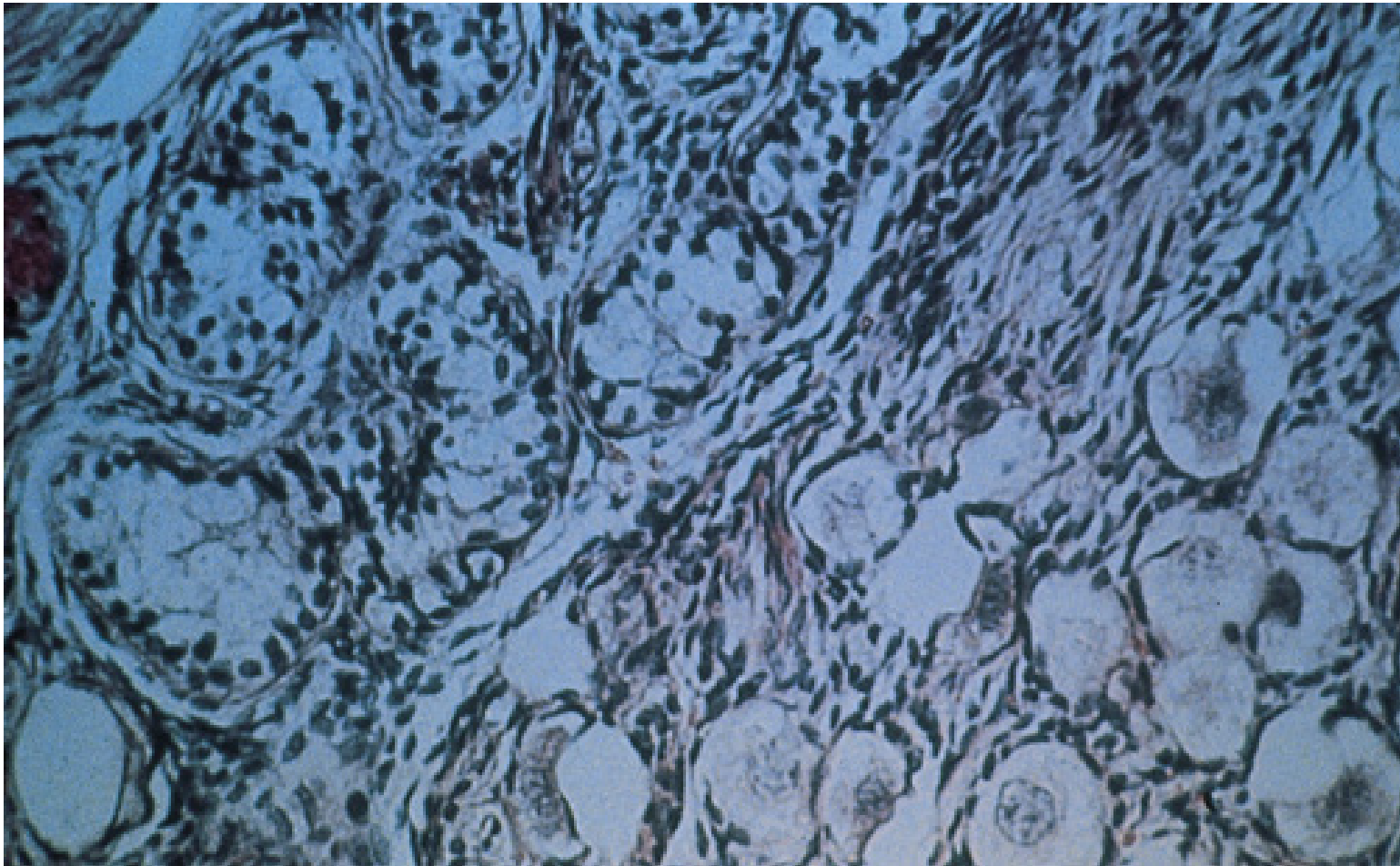
# True Hermaphroditism/ Ovotesticular DSD







# True hermaphroditism





# Classification of Genital Ambiguity

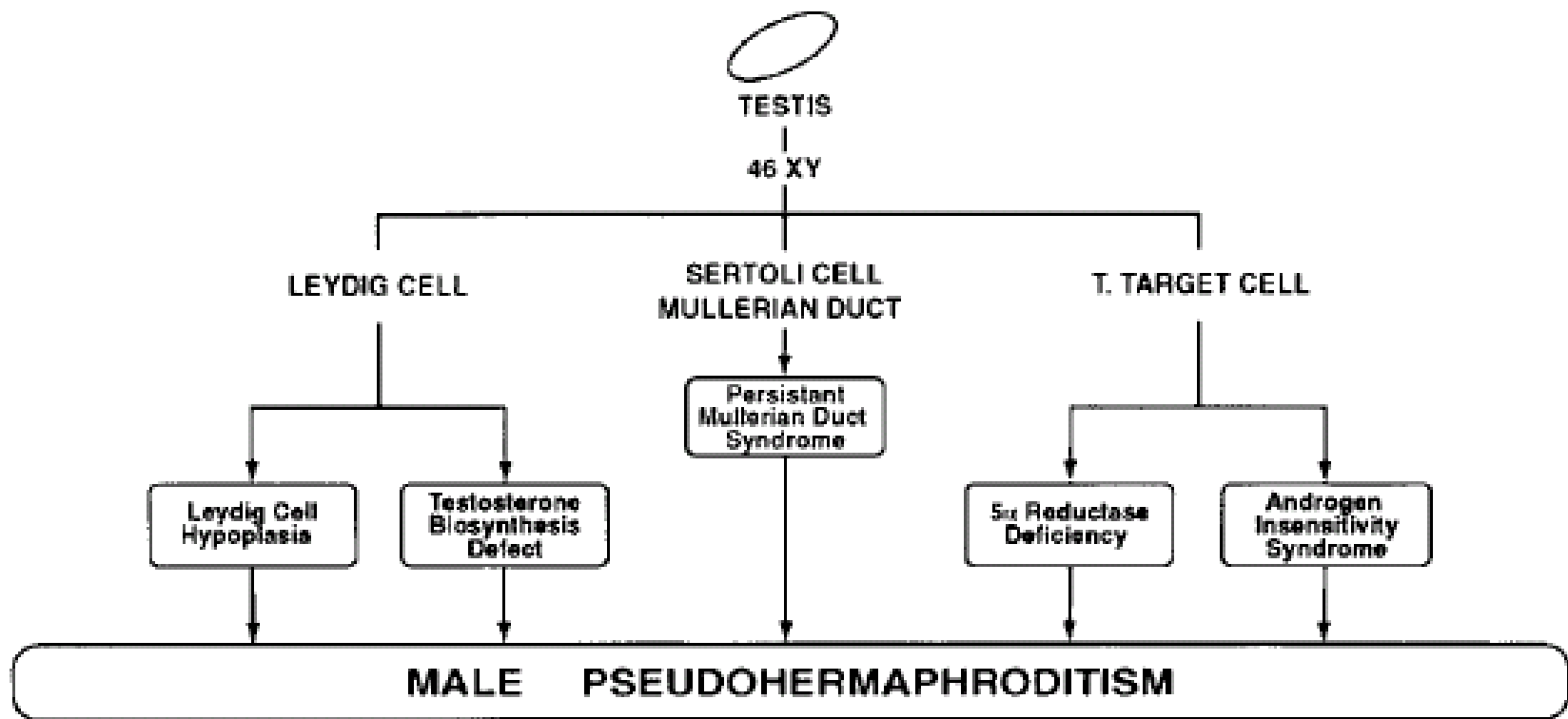
**Gonadal  
Dysgenesis**

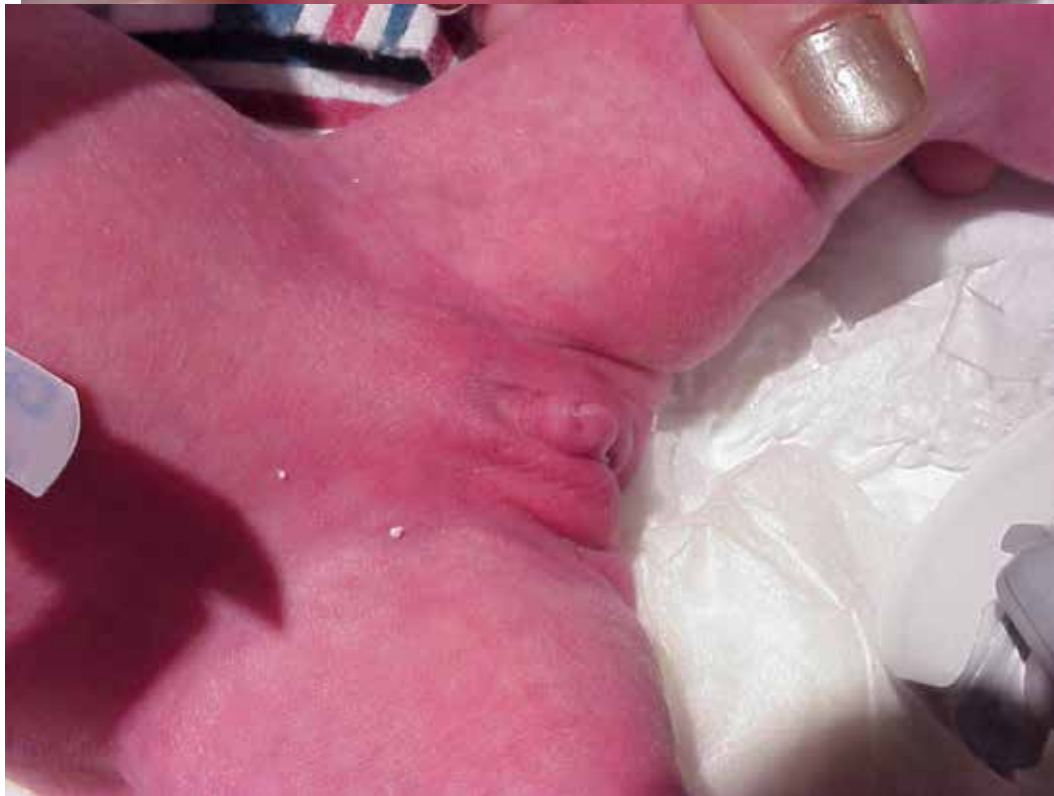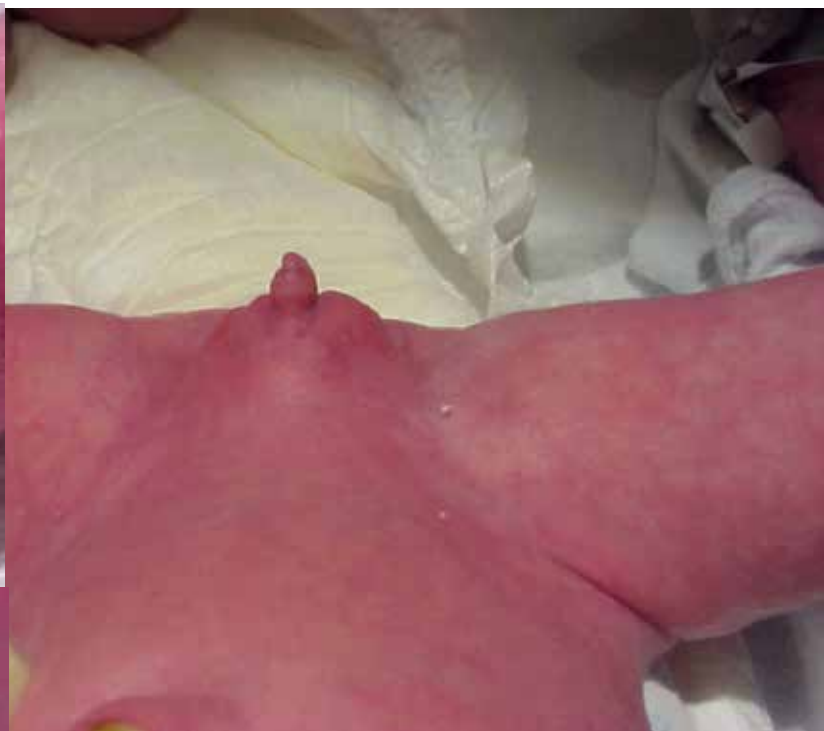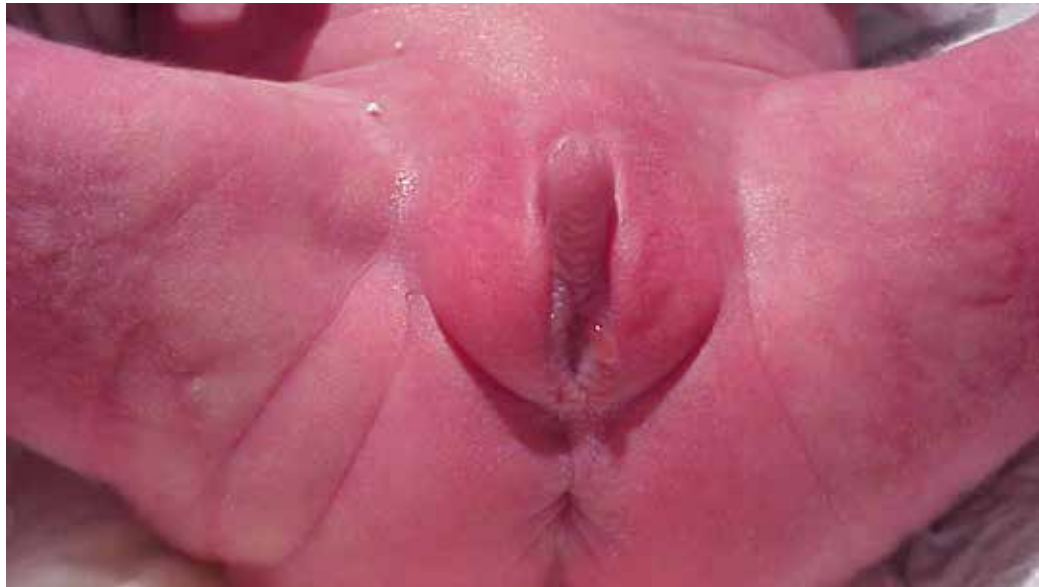**True  
Hermaphrodite**

**Under-virilized  
Male**

**Virilized  
Female**

**Insufficient stimulation  
Leydig cell agenesis  
Inability to produce testosterone  
Inability to produce DHT  
Androgen receptor defect**



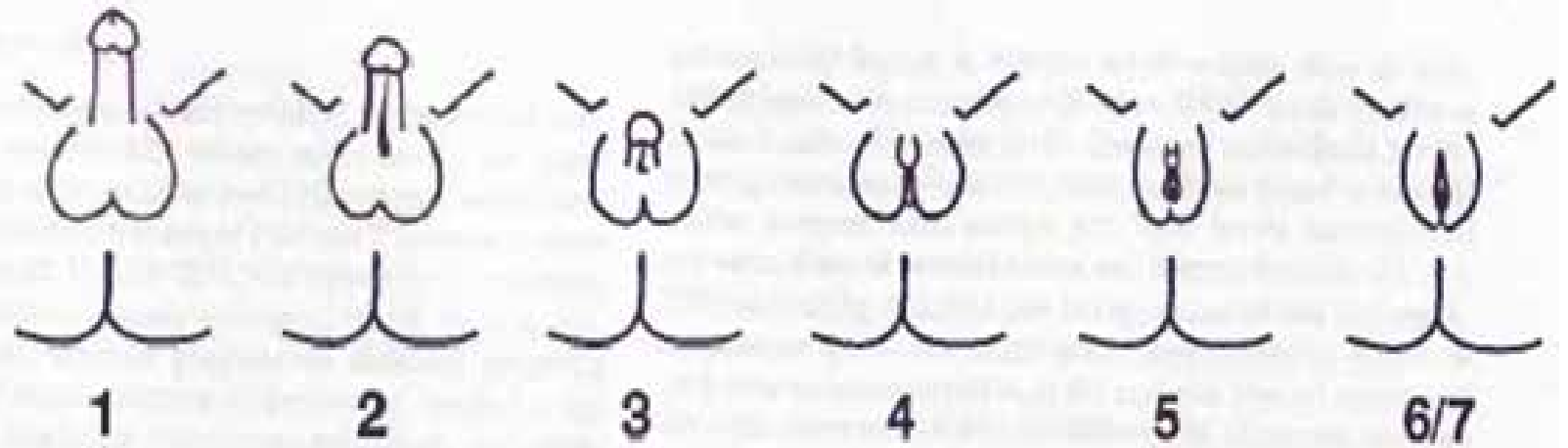


**Undervirilized male**  
**Male Pseudohermaphrodite**

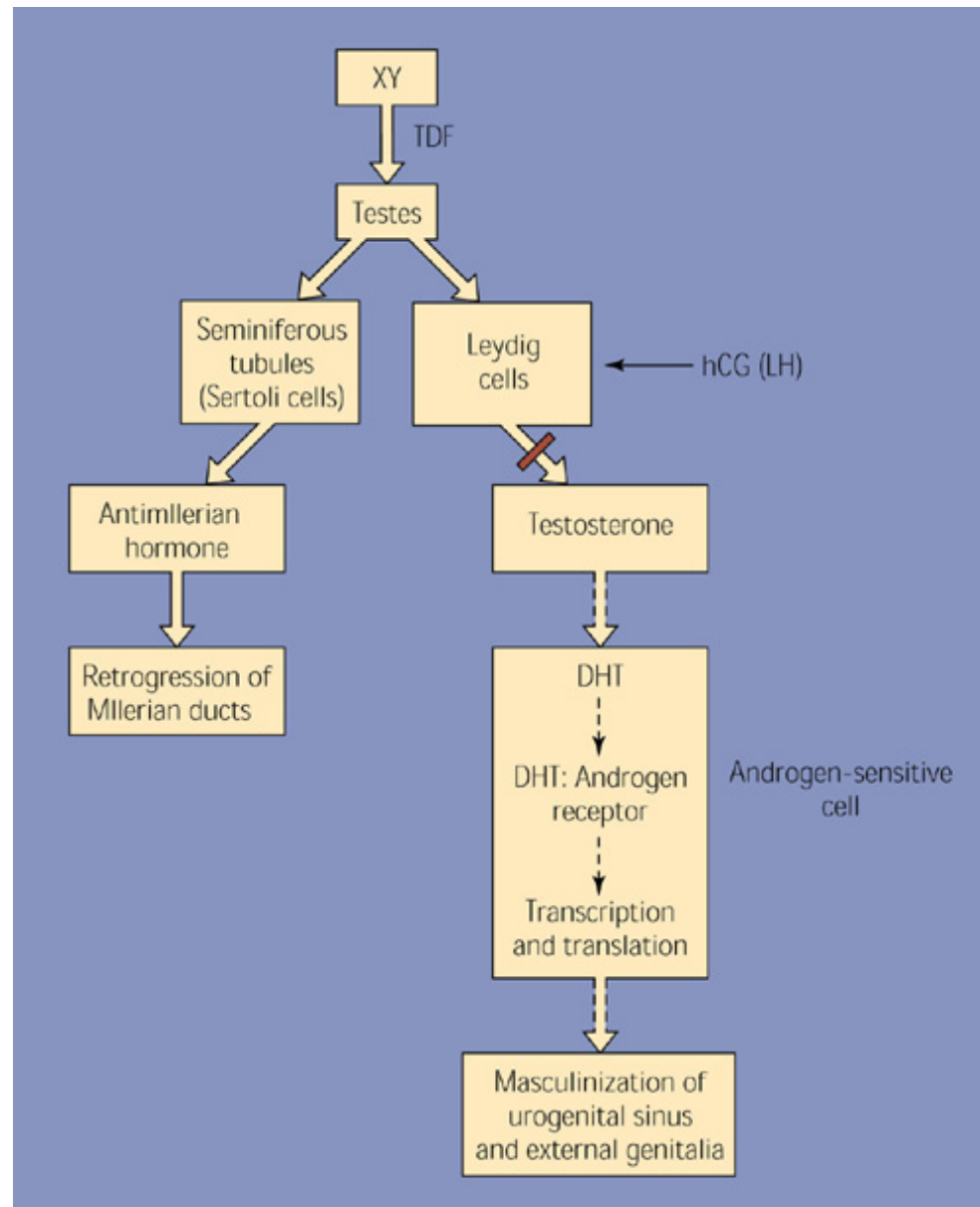
**Absent Uterus**  
**46,XY**

# Spectrum of Undervirilization

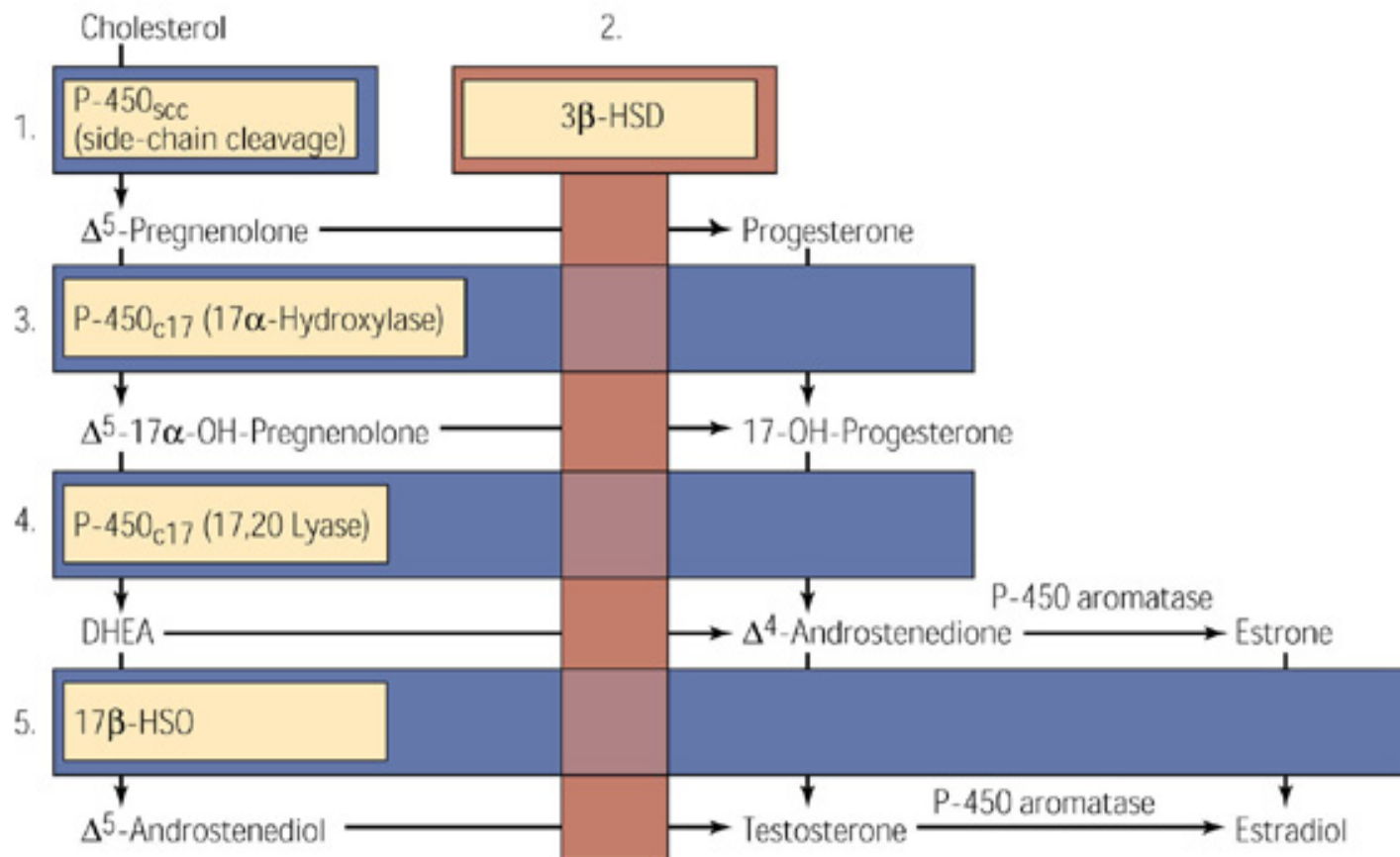
QUIGLEY ET AL.



# Testosterone block in male sex determination



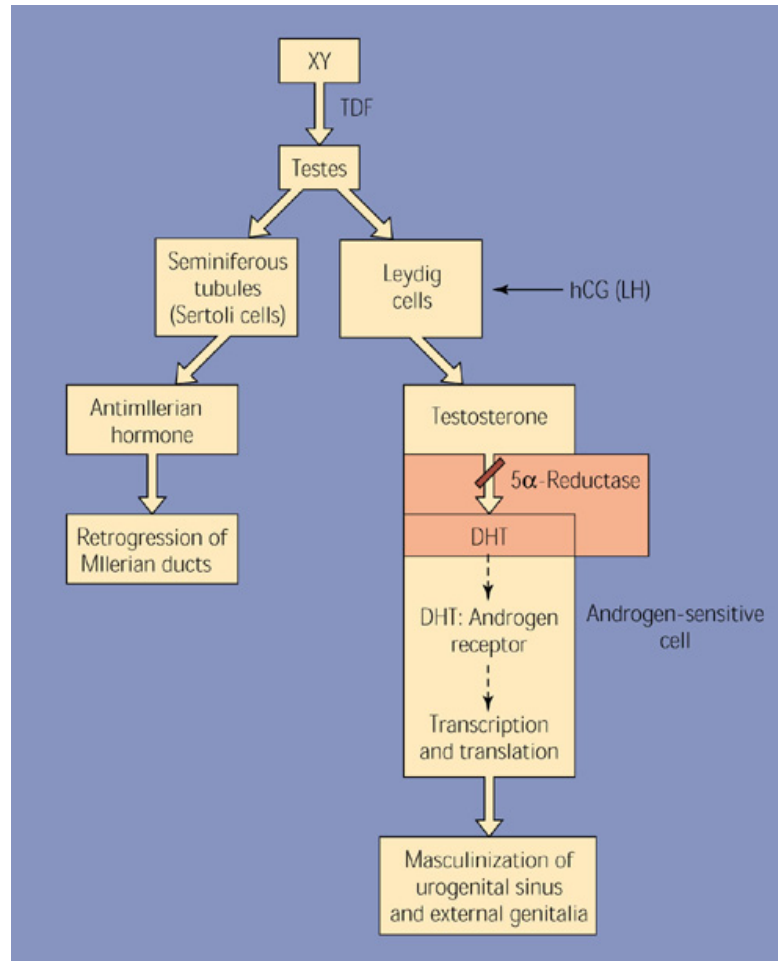
# Enzymatic defects in biosynthetic pathway for testosterone



# Salient features in Androgenic steroid disorders

	<b>P450scc</b>	<b>3bHSD</b>	<b>17OH</b>	<b>17 bHSD</b>
<b>Karyotype</b>	XY	XY	XY	XY
<b>Inheritance</b>	AR	AR	AR	AR
<b>Gonads</b>	TESTES	TESTES	TESTES	TESTES
<b>Wolfian</b>	-	NL	NL	NL
<b>Mullerian</b>	ABSENT	ABSENT	ABSENT	ABSENT
<b>Genitalia</b>	↗	↗	↗	↗
<b>Habitus</b>	Adrenal Insufficiency	Adrenal Insufficiency	Hypertension	

# Male pseudohermaphroditism from 5 $\alpha$ -reductase deficiency

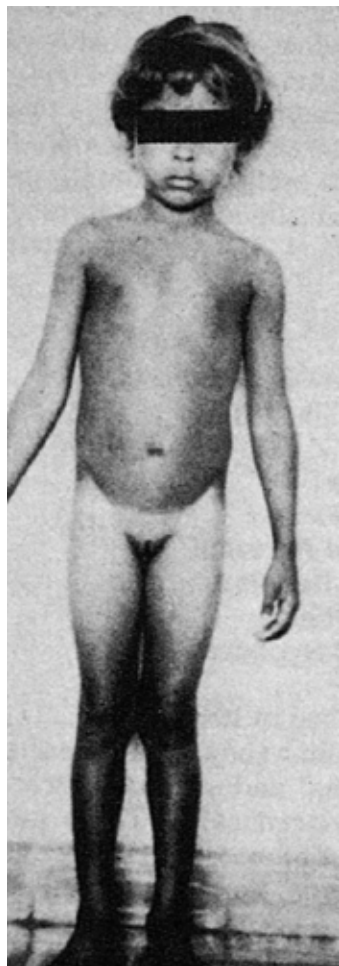



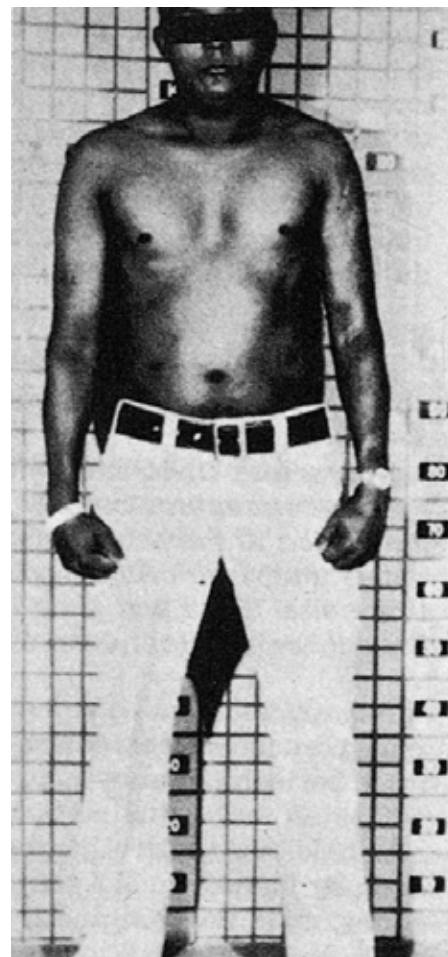
# 5 $\alpha$ -Reductase deficiency

- **AR Mutation in 5 $\alpha$ R2 gene**
- **Impaired conversion of T to DHT in target tissues**
- **Impaired development of penis, scrotum, urethra and prostate**
- **At birth, ambiguous genitalia with hypospadiac phallus and blind vaginal pouch, normal testes**
- **At puberty virilize without gynaecomastia**

# 46,XY karyotype with 5a-reductase deficiency



Prepubertal "girl"



Post-pubertal boy

# Complete androgen insensitivity

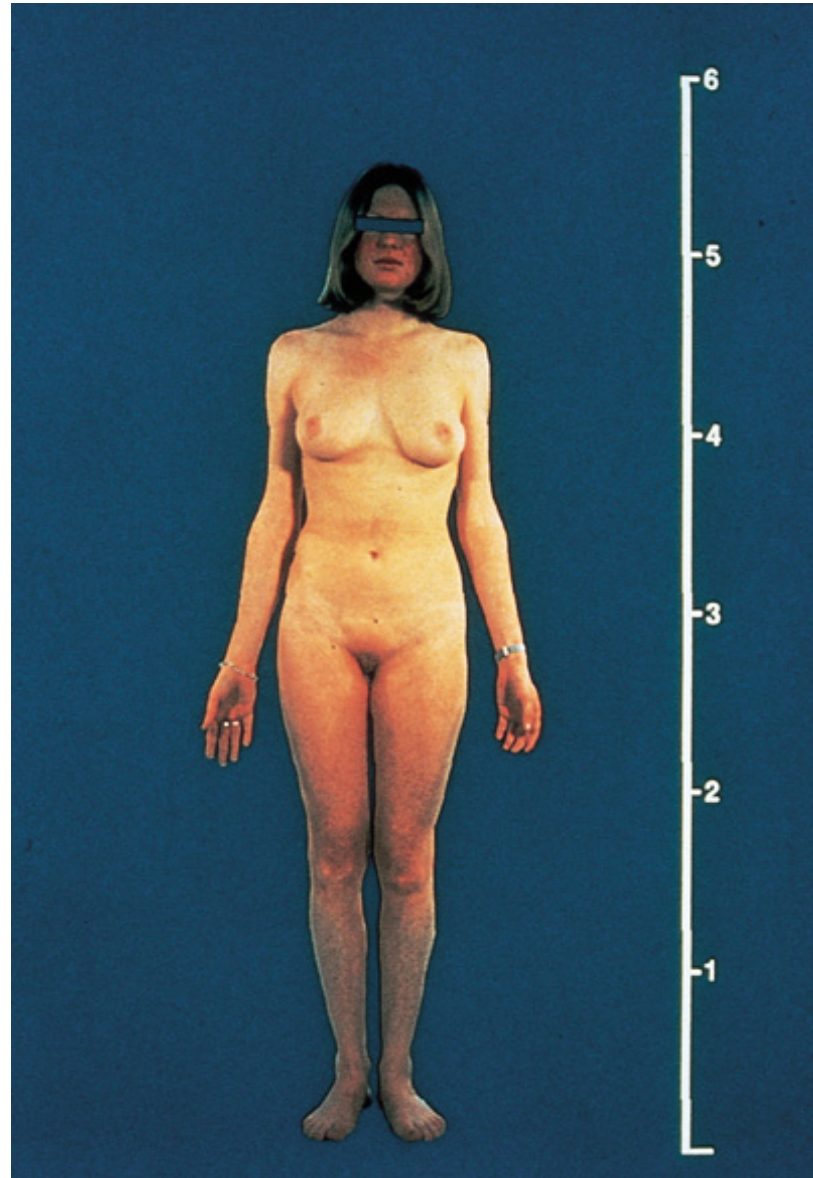
**18y old “female”**

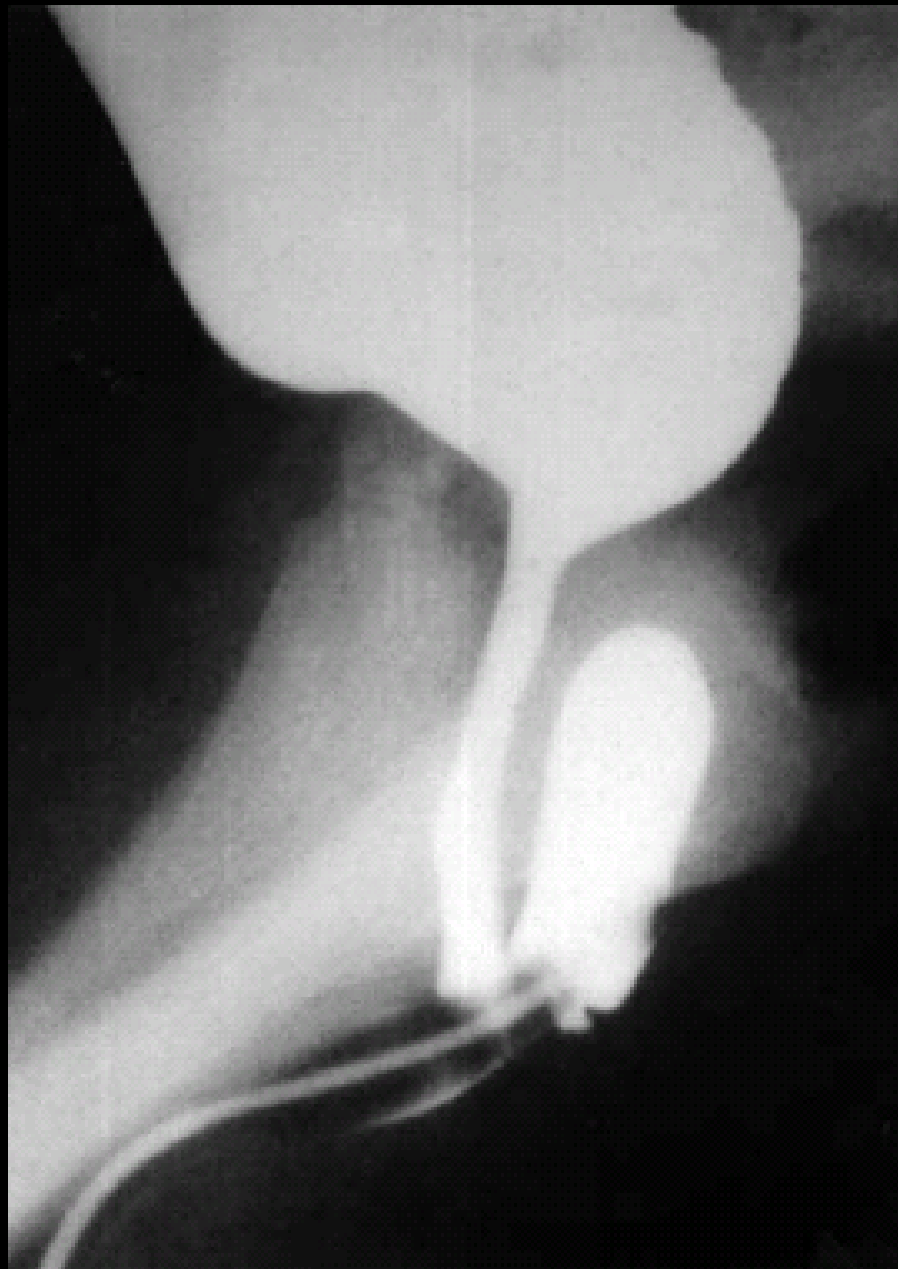
**Tanner V breast**

**Absent Pubic hair**

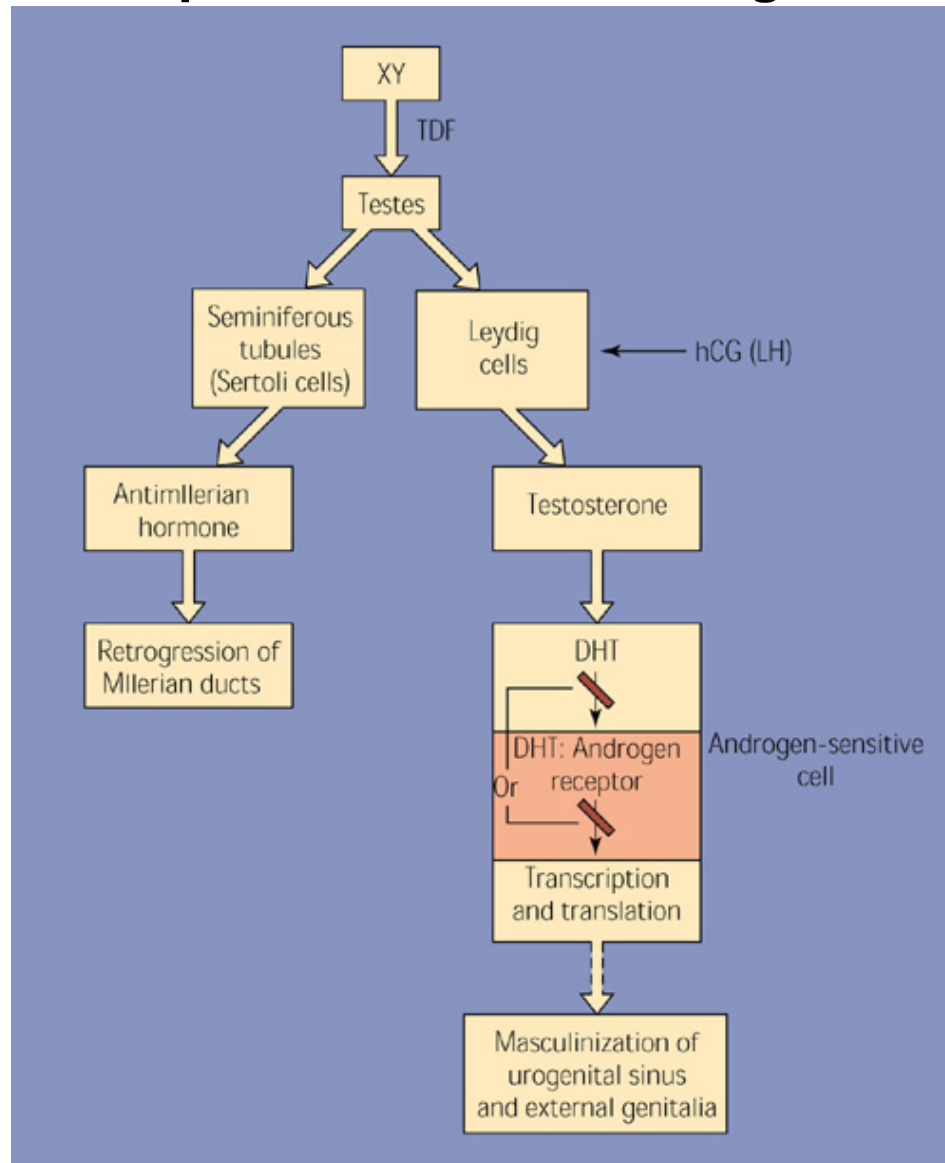
**Blind vagina**

**46,XY**

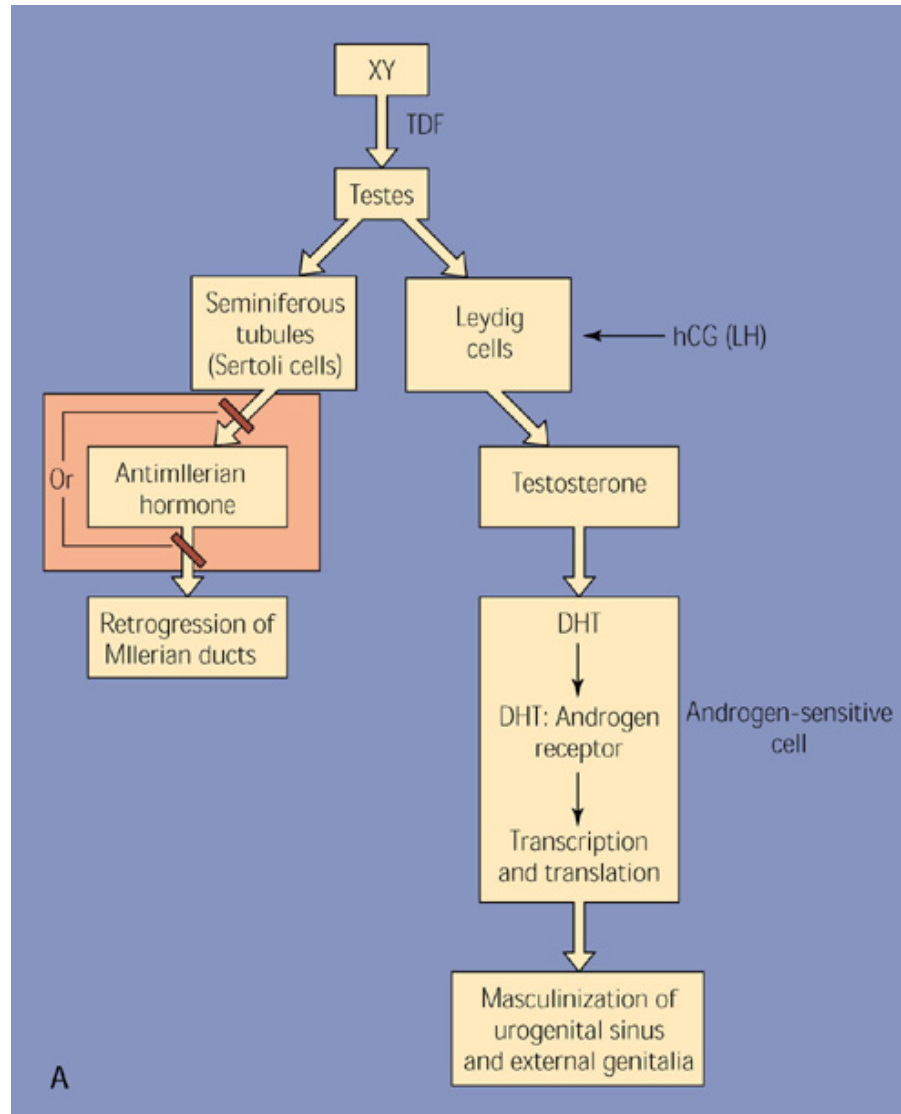




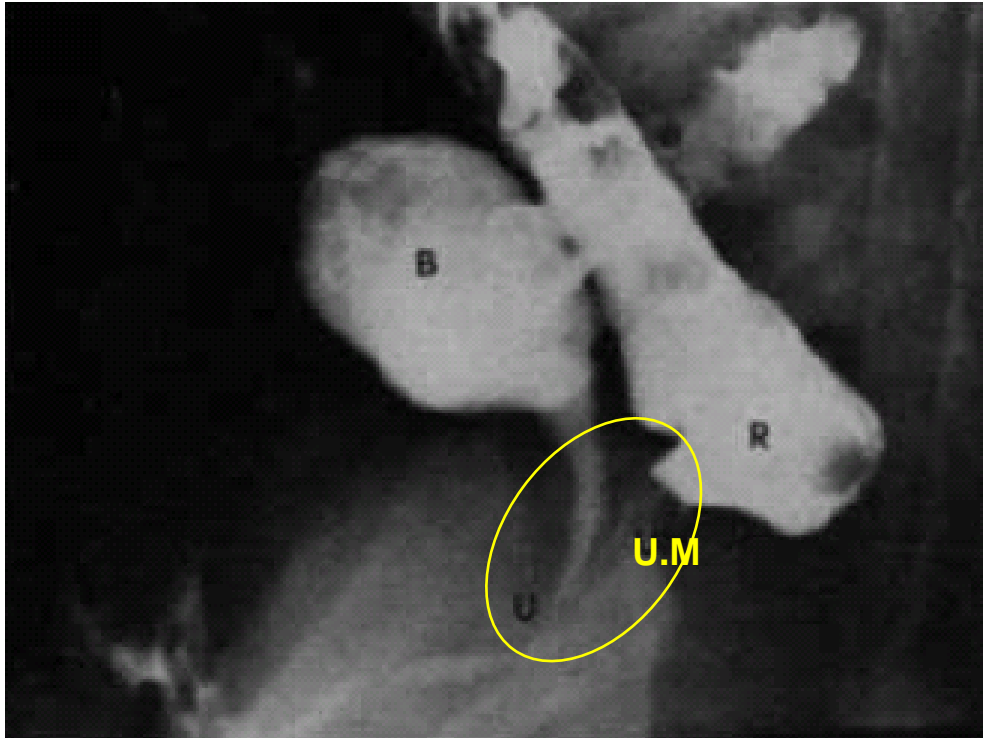
# Male pseudohermaphroditism from androgen resistance



# Persistent Mullerian duct syndrome

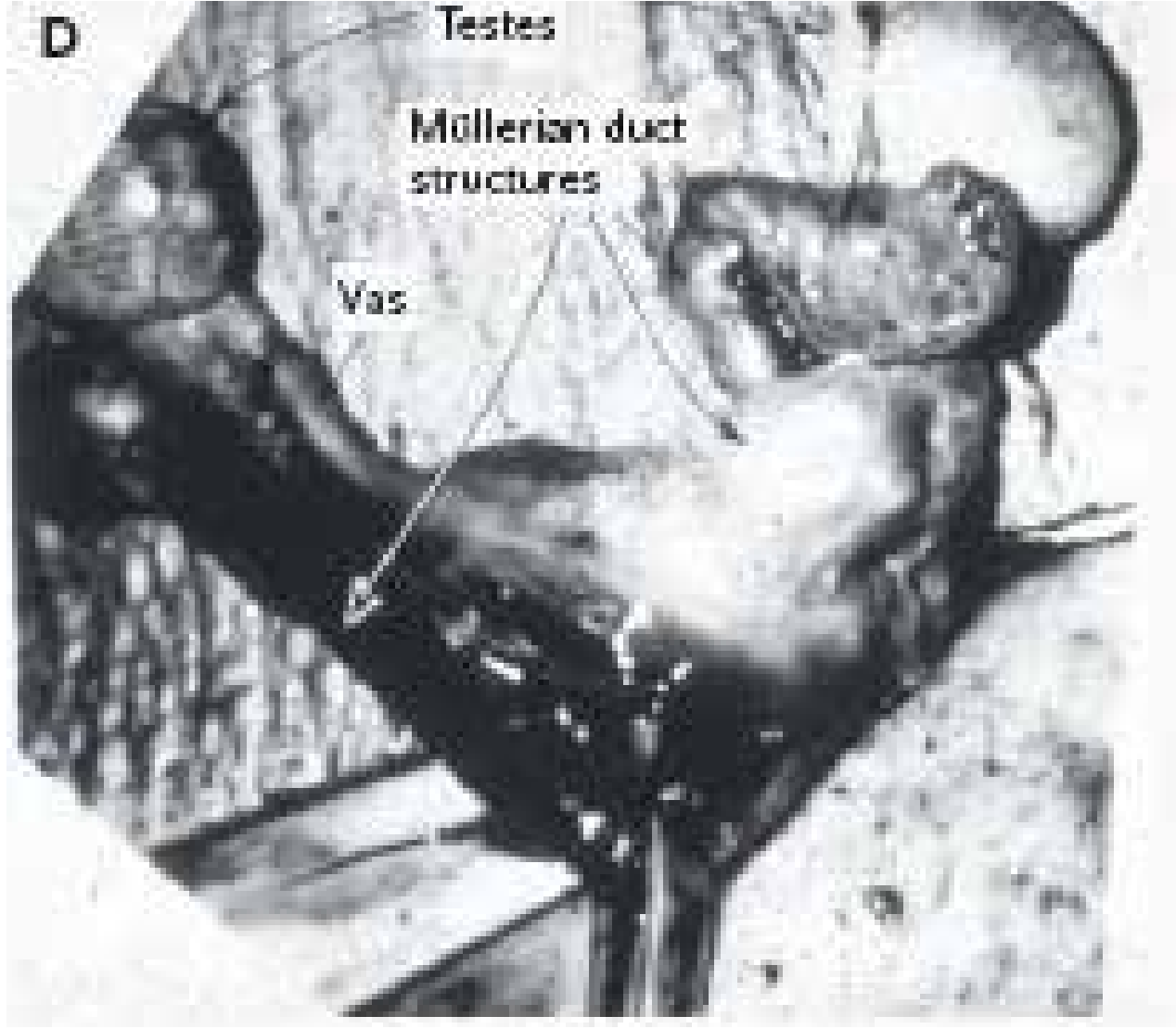


# Persistent Mullerian Duct Syndrome (Hernia uteri inguinale)



- 46 XY
- Male genitalia
- Undescended testes
- X-linked recessive

**U.M. Utriculus masculinus**





# Classification of Genital Ambiguity

**Gonadal  
Dysgenesis**

**True  
Hermaphrodite**

**Under-virilized  
Male**

**Virilized  
Female**

**CAH**  
**Excess maternal androgens**  
**Ovarian tumours**  
**Adrenal tumours**  
**Luteoma of pregnancy**



**OVARY**

**46 XX**

**FETUS**

**MOTHER**

**Placental  
Aromatase  
Deficiency**

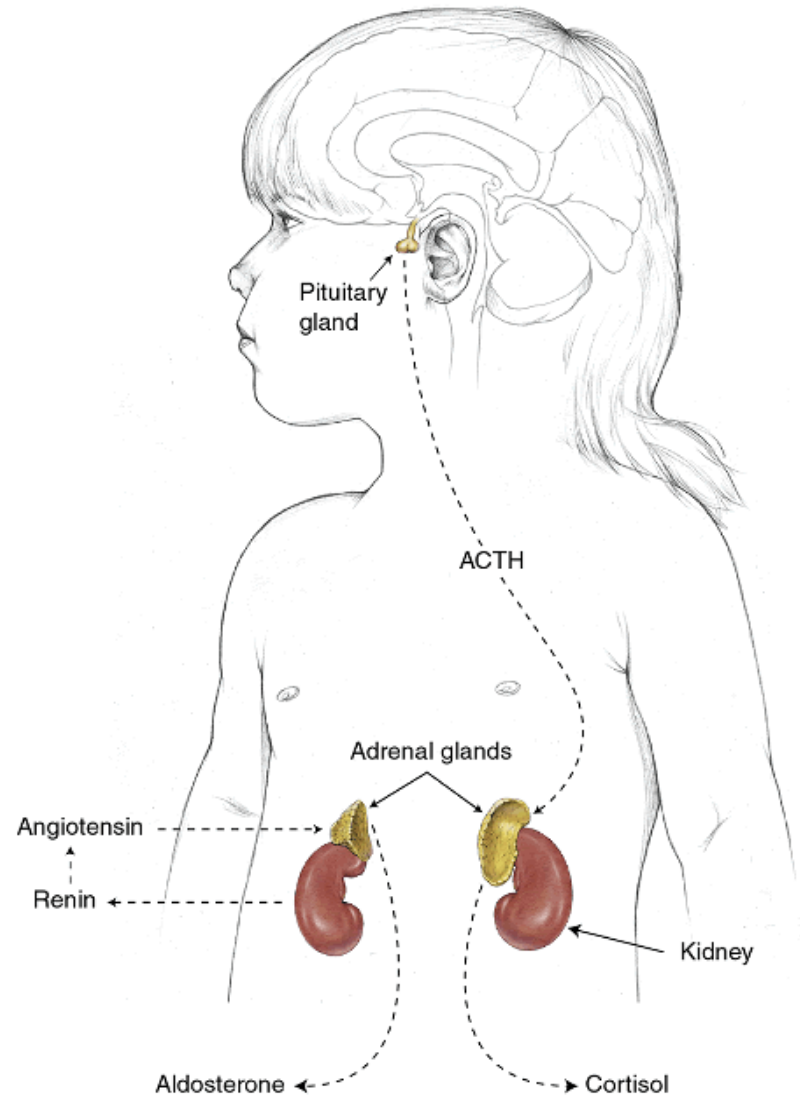
**Congenital  
Adrenal  
Hyperplasia**

**Medication**

**Hormone  
Secreting  
Tumor**

**FEMALE PSEUDOHERMAPHRODITISM**

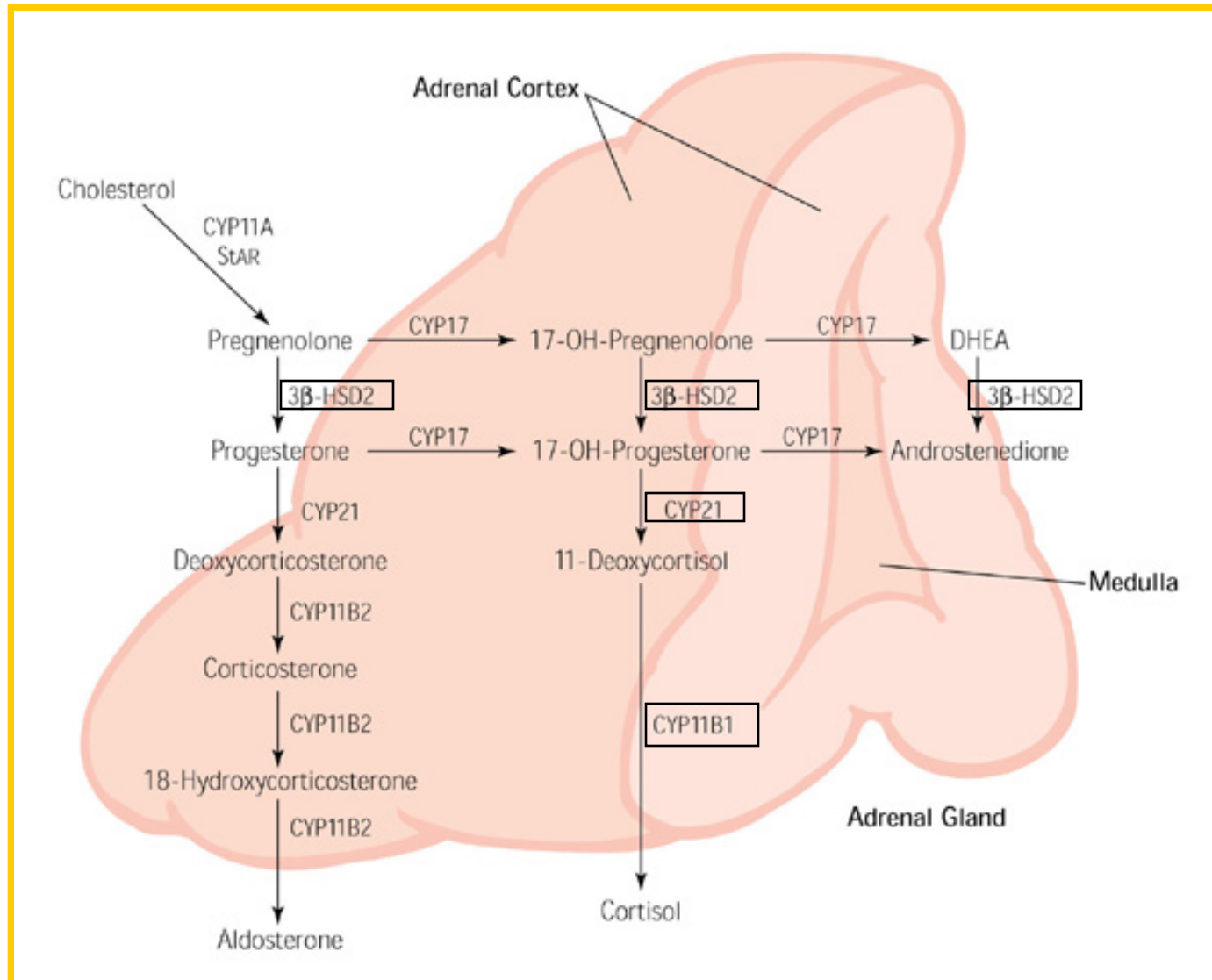
# Congenital Adrenal Hyperplasia



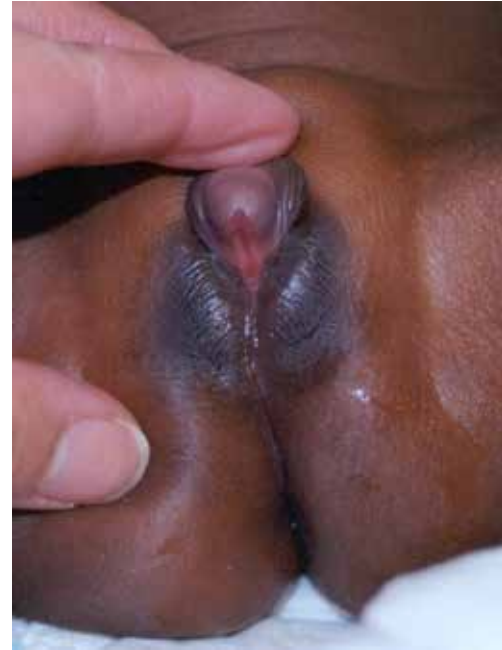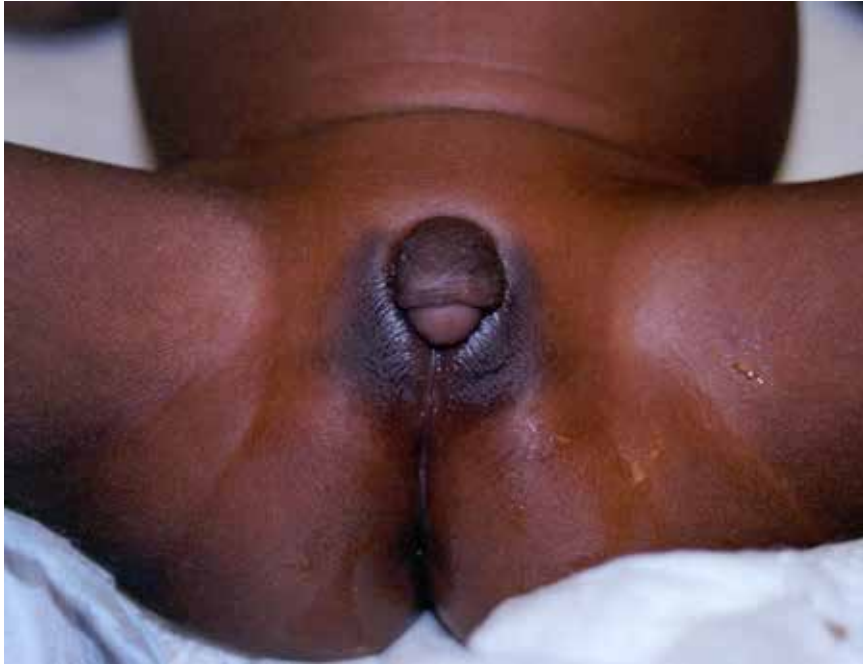# Basics

- 21-OH def (CYP21) 95% of cases
  - Salt-wasting
  - Simple virilizing
  - Non-classic (late onset)
- 11-OH (CYP11)
- 3 $\beta$ -HSD

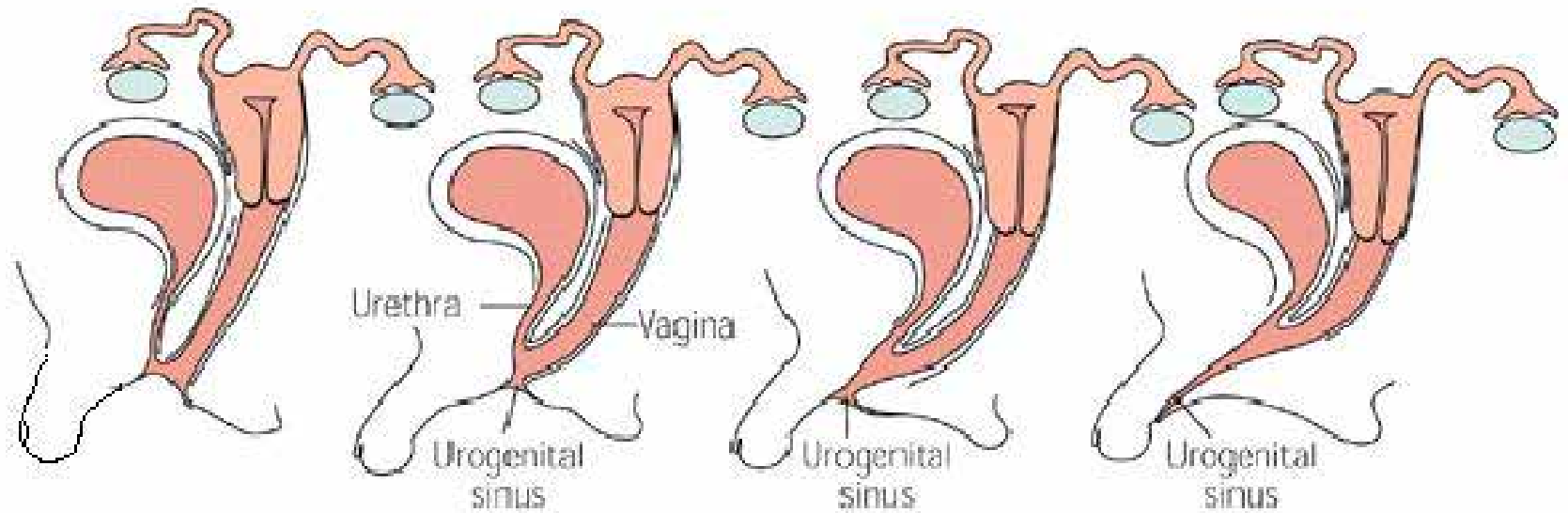
# Congenital Adrenal Hyperplasia



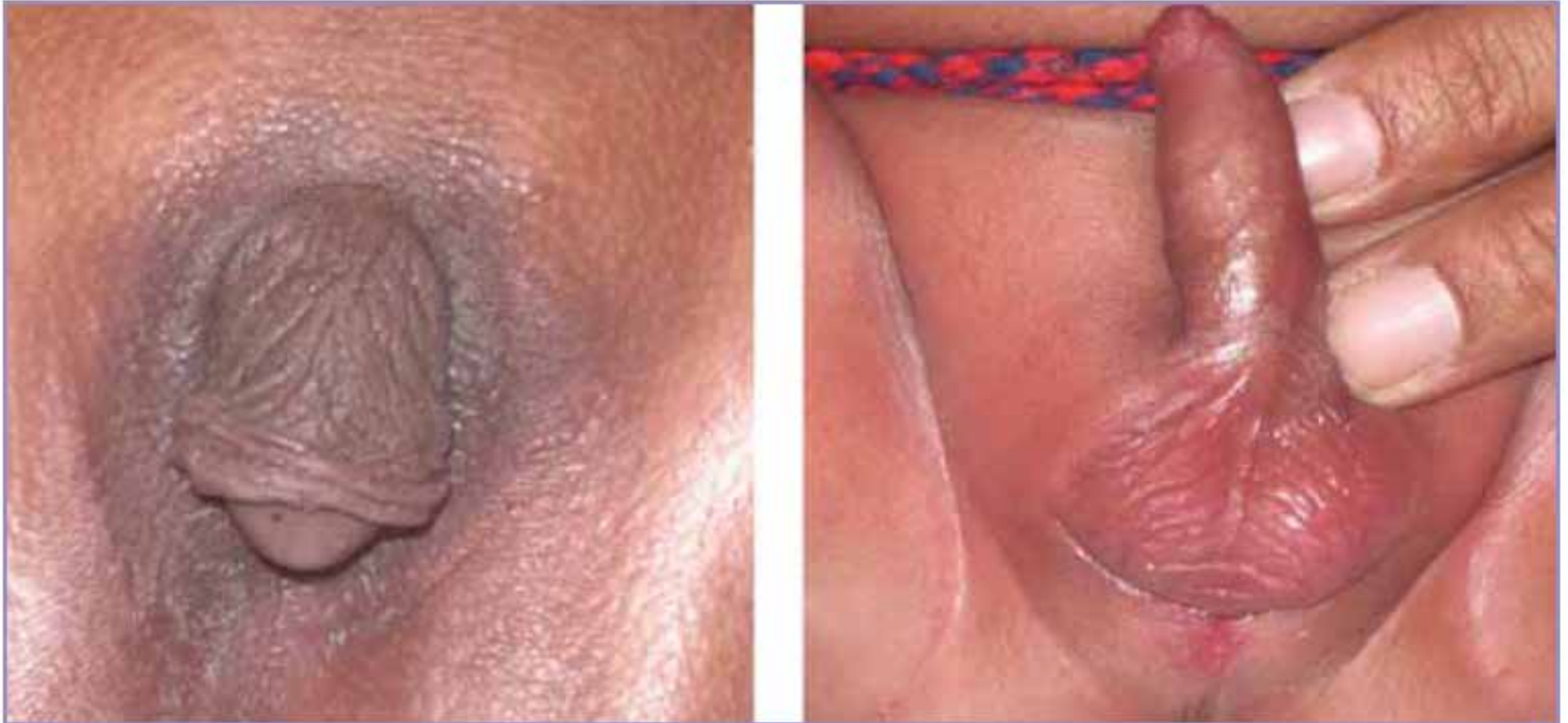# CAH- 21-OH deficiency



# Spectrum of Masculinization of female external genitalia

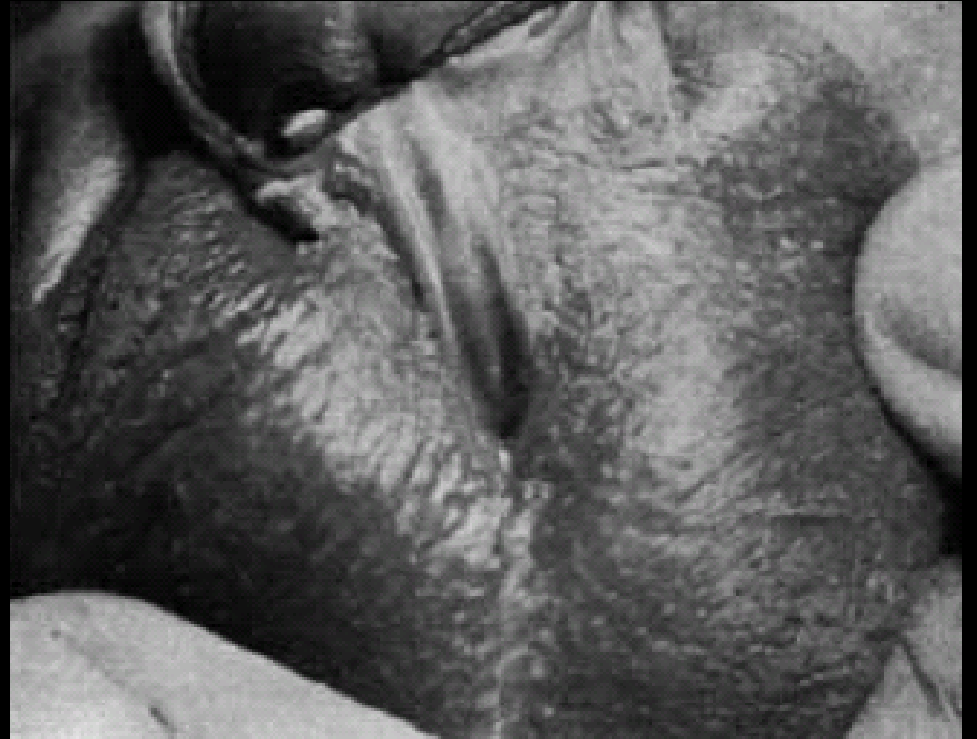
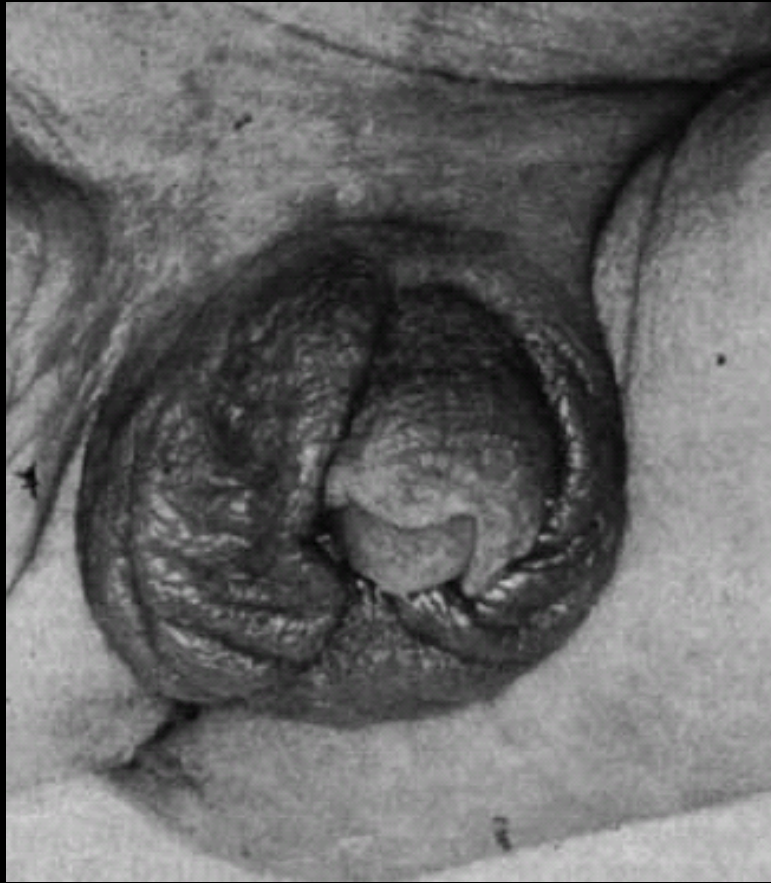
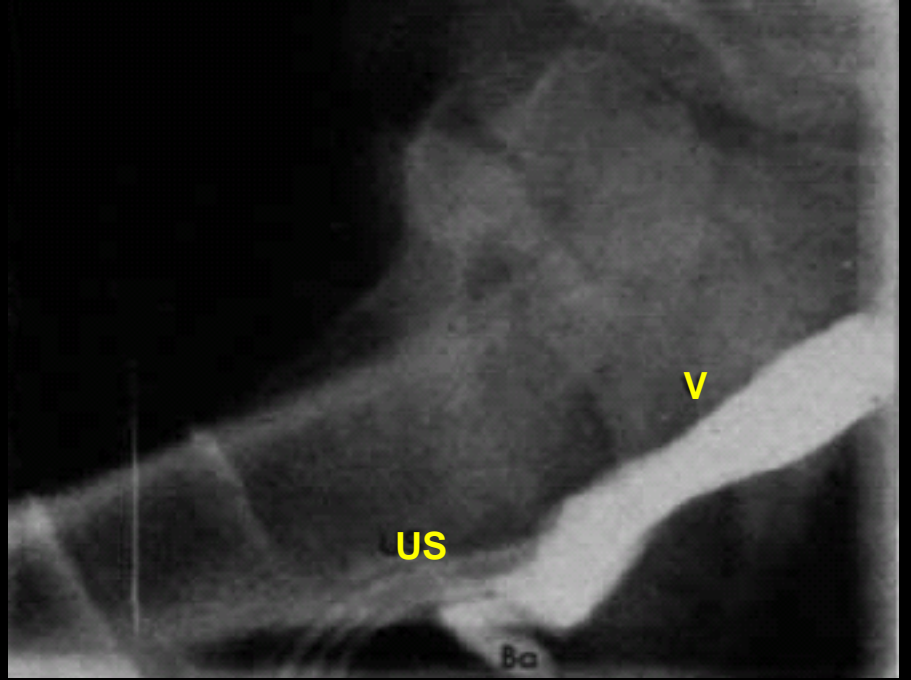
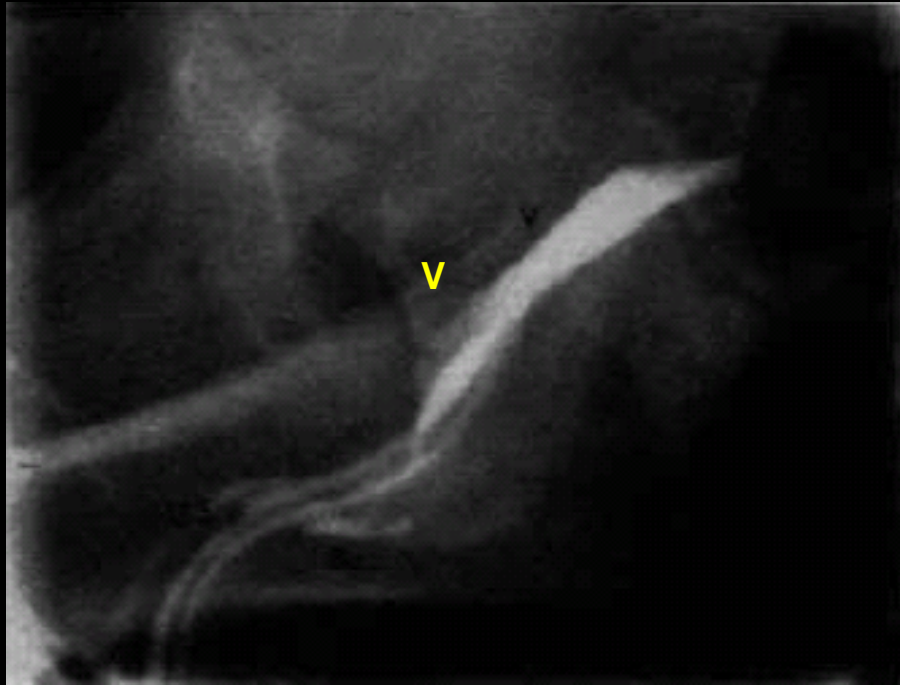
# Spectrum of virilization CAH

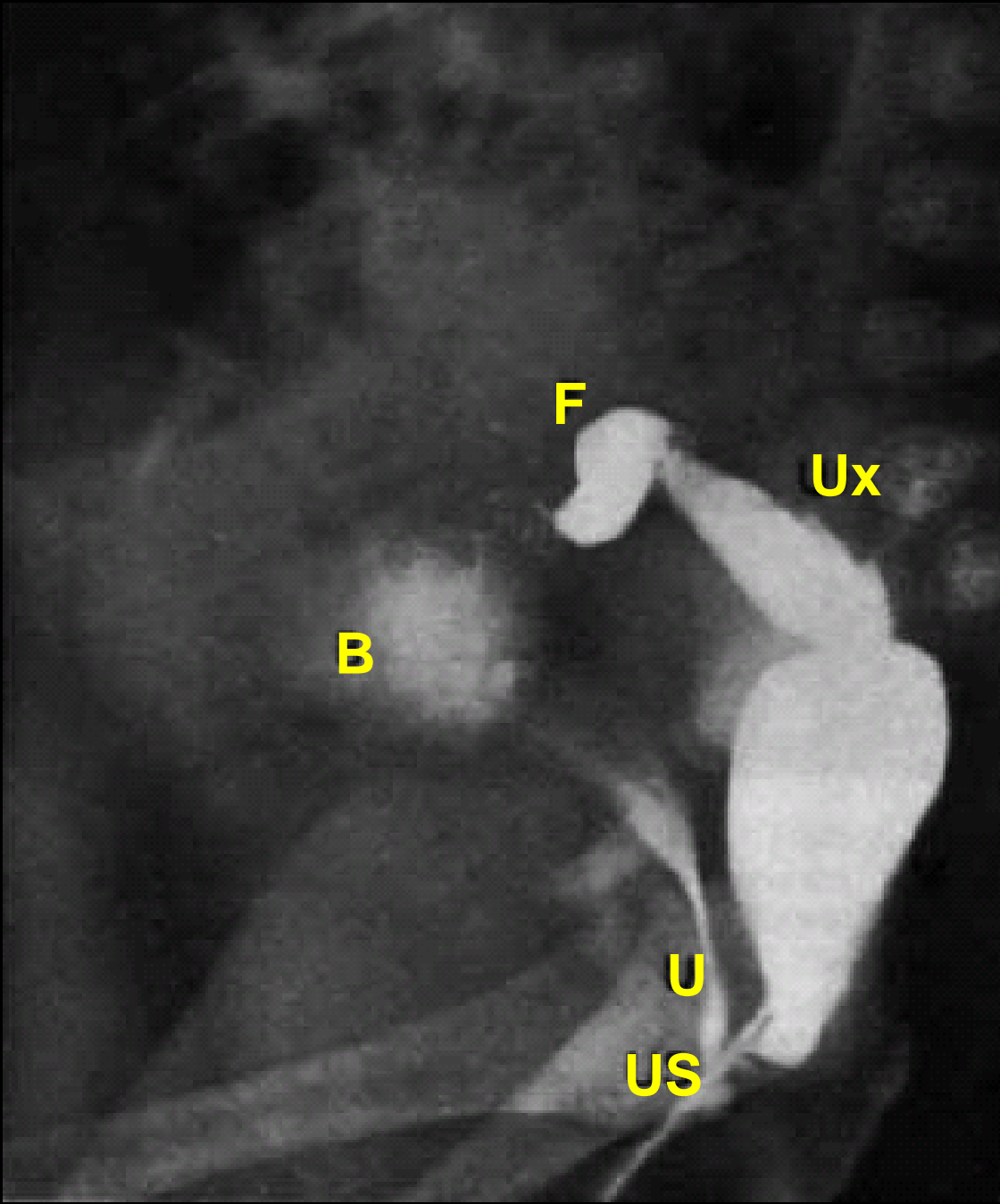

*Figure 2: Spectrum of virilisation of a female. (46 XX with CAH)*

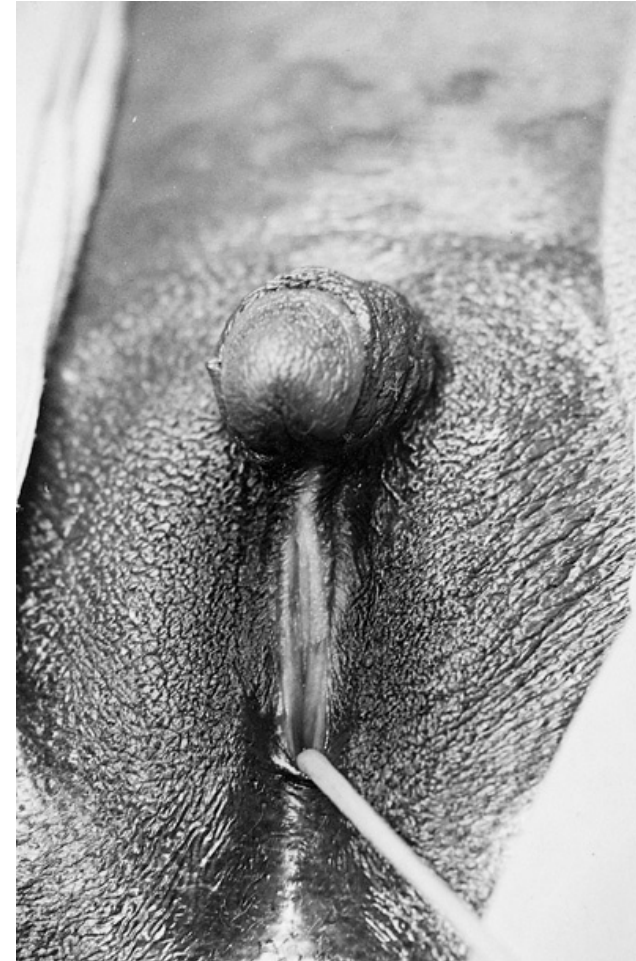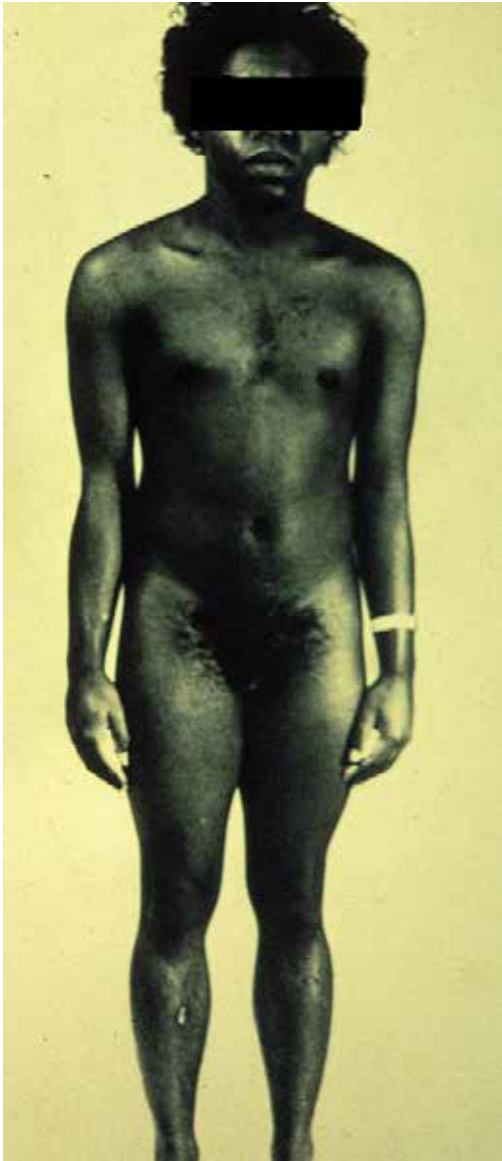








## 21-Hydroxylase (P-450<sub>c21</sub>) deficiency



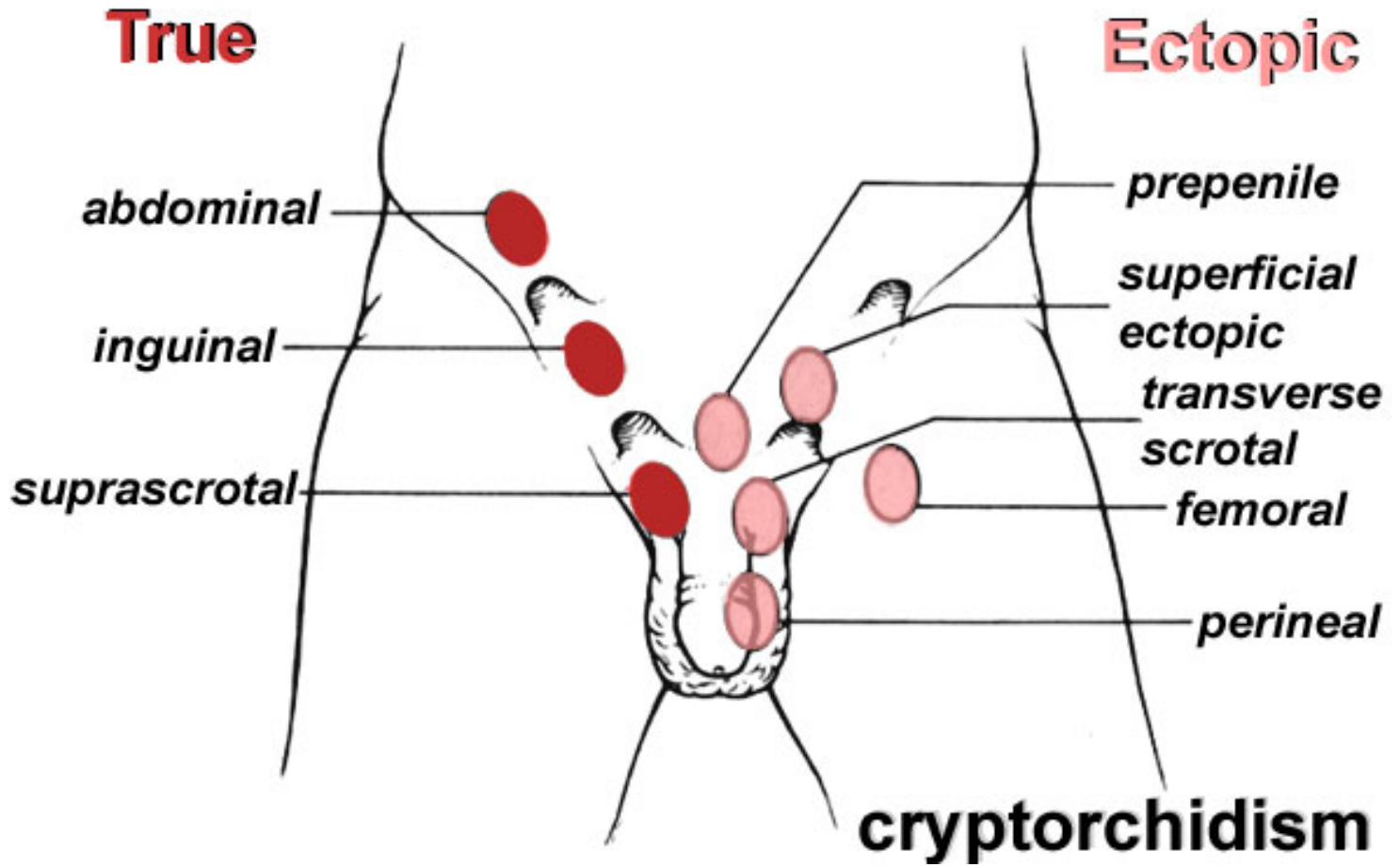
18y old gender identity concern

# The Incidence of Intersexuality in children with Cryptorchidism and Hypospadias

Martin Kaefer et al, The Journal of Urology 1999

- Cryptorchidism
  - 1/30 full-term
  - 1/120 1 year olds
- Hypospadias 1/300
- Children with hypospadias *and* cryptorchidism have a 27% incidence of intersexuality
- Both are due to inadequate androgen action

# Cryptorchid testes

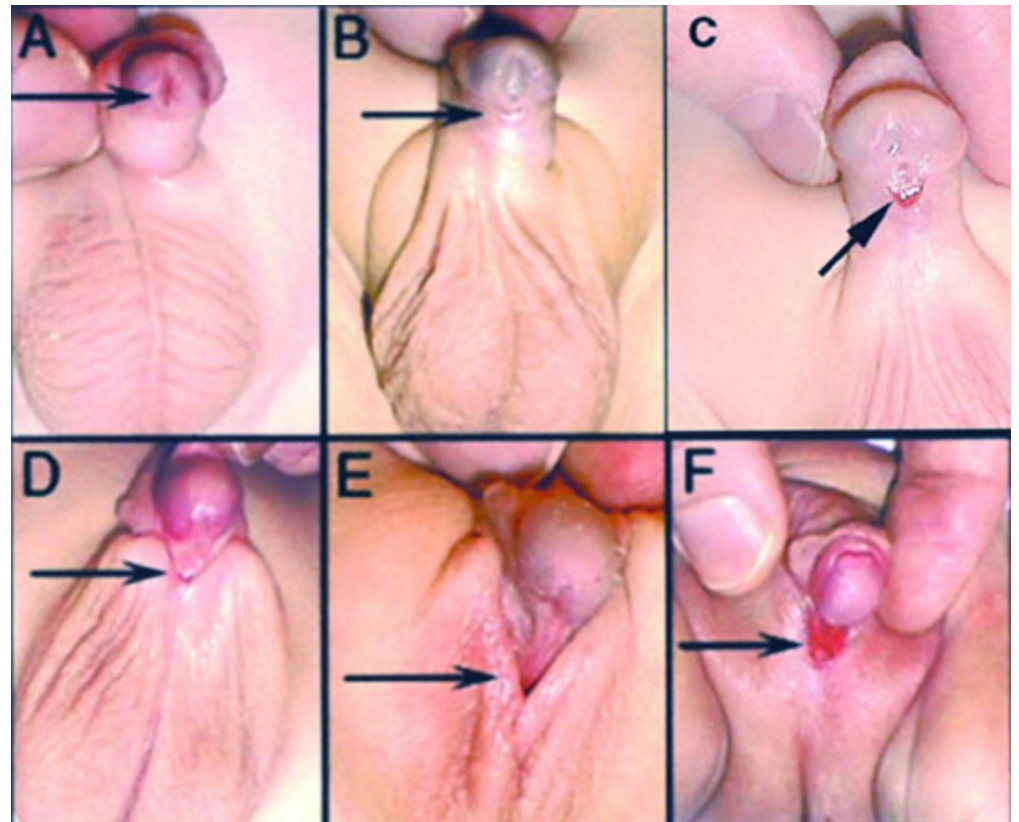


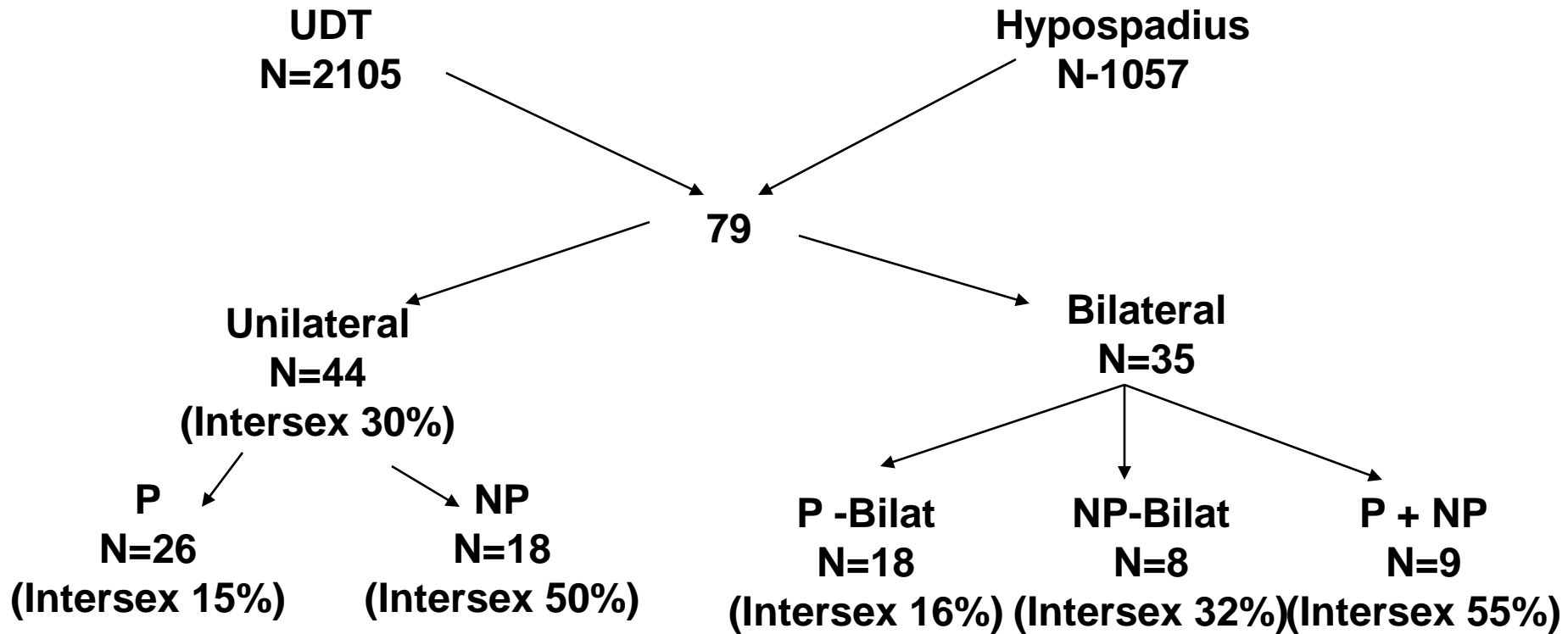
## cryptorchidism

- Palpable
- Non-palpable

# Hypospadias

- **Hypospadias**
  - **Anterior**
    - Glanular
    - Coronal
  - **Mid**
    - distal penile
    - proximal mid shaft
  - **Posterior**
    - Penoscrotal
    - Scrotal
    - Perineal





**MGD = 6**  
**TH = 3**  
**5aR = 2**  
**47XXY = 2**

**MGD = 5**  
**TH = 2**  
**PAIS = 3**  
**Vanish testes = 1**



# Meatal Position

Meatal position	Intersex
anterior (33%)	8%
mid (26%)	5%
Posterior (41%)	<b>65%</b>

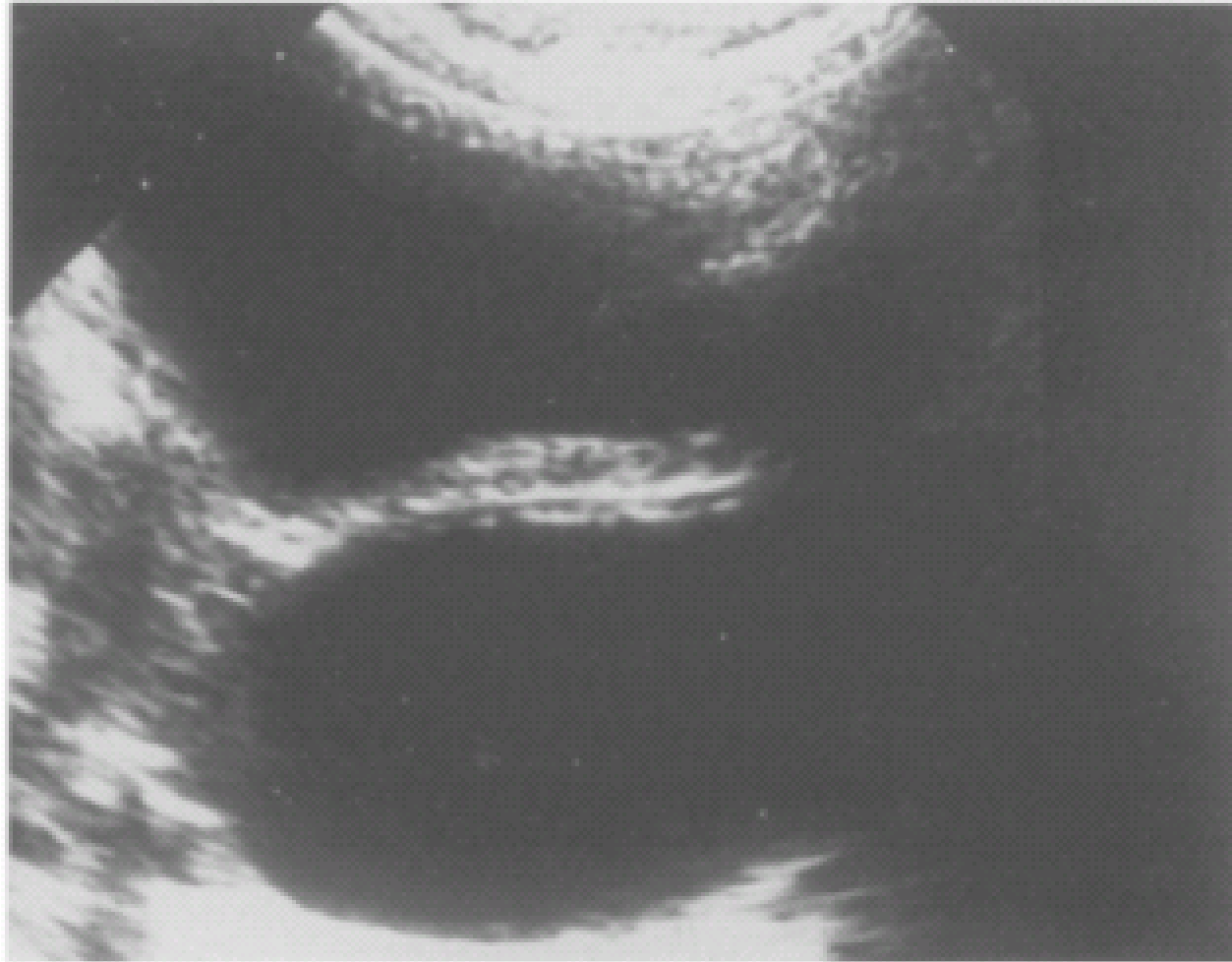


Fig. 1 Pelvic ultrasound in a female pseudohermaphrodite with congenital adrenal hyperplasia showing hydrocolpos consistent with a urogenital sinus malformation.

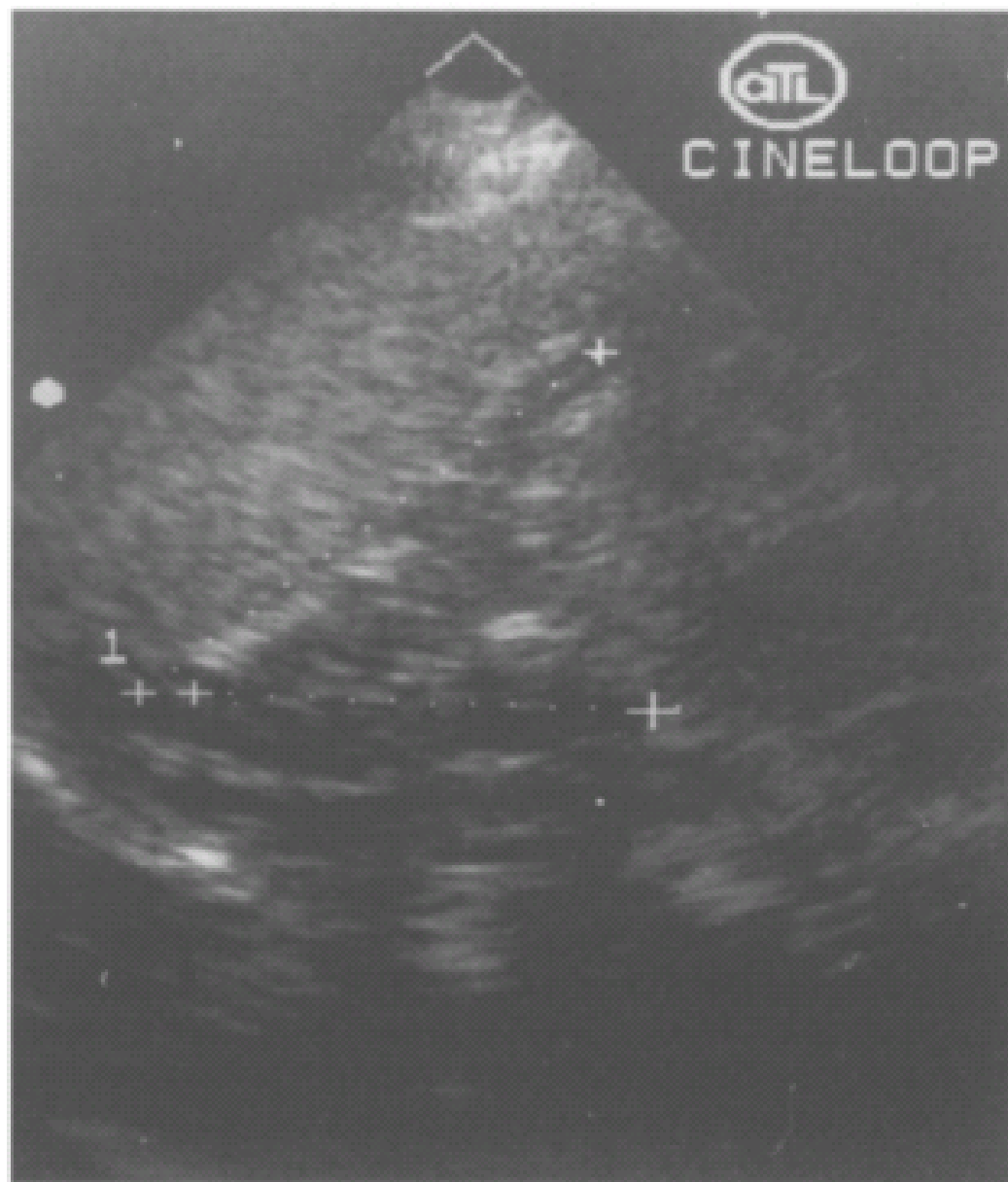
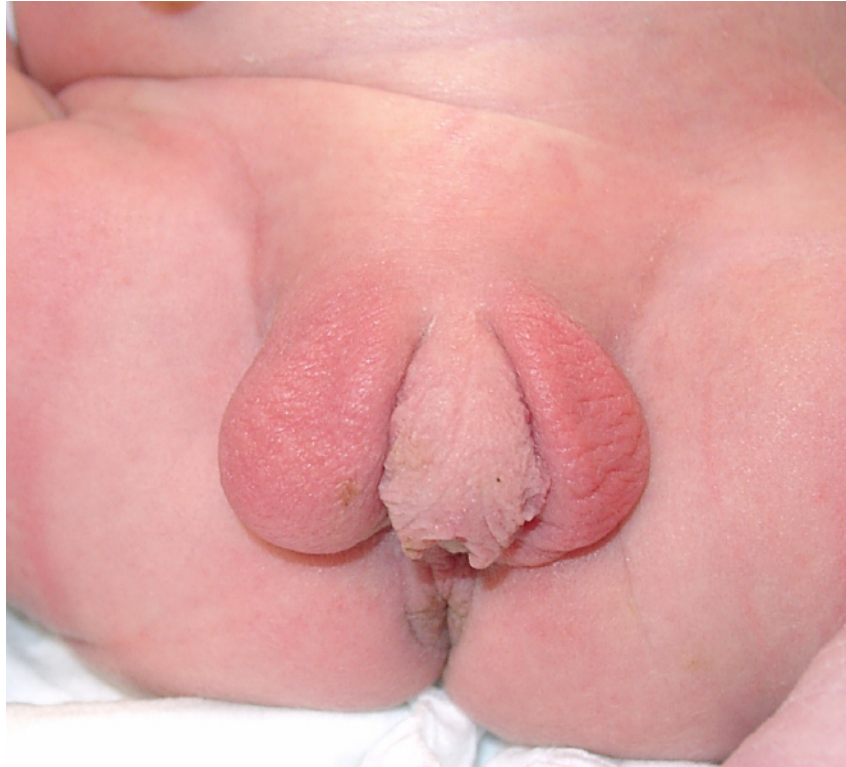

Fig. 3 Ultrasound in a female pseudohermaphrodite with congenital adrenal hyperplasia shows an enlarged adrenal gland.

# Ambiguous Genitalia



What to do?

- Call for help
- Karyotype
- Urgent electrolytes
- 17-OHP, DHEAS, androstenedione, testosterone, DHT
- US
- Genitogram
- HCG stimulation
- ACTH stimulation test
- MIS
- Call for help

# Management


- Specialist team
  - Paediatrician (endocrinologist)
  - Surgeon
  - Genetics
  - Parents

# Issues

- Sex assignment
- Surgery
  - Y/N
  - Timing
- Follow-up
- Disclosure

# Tying it all together

To prevent this





# Tying it all together

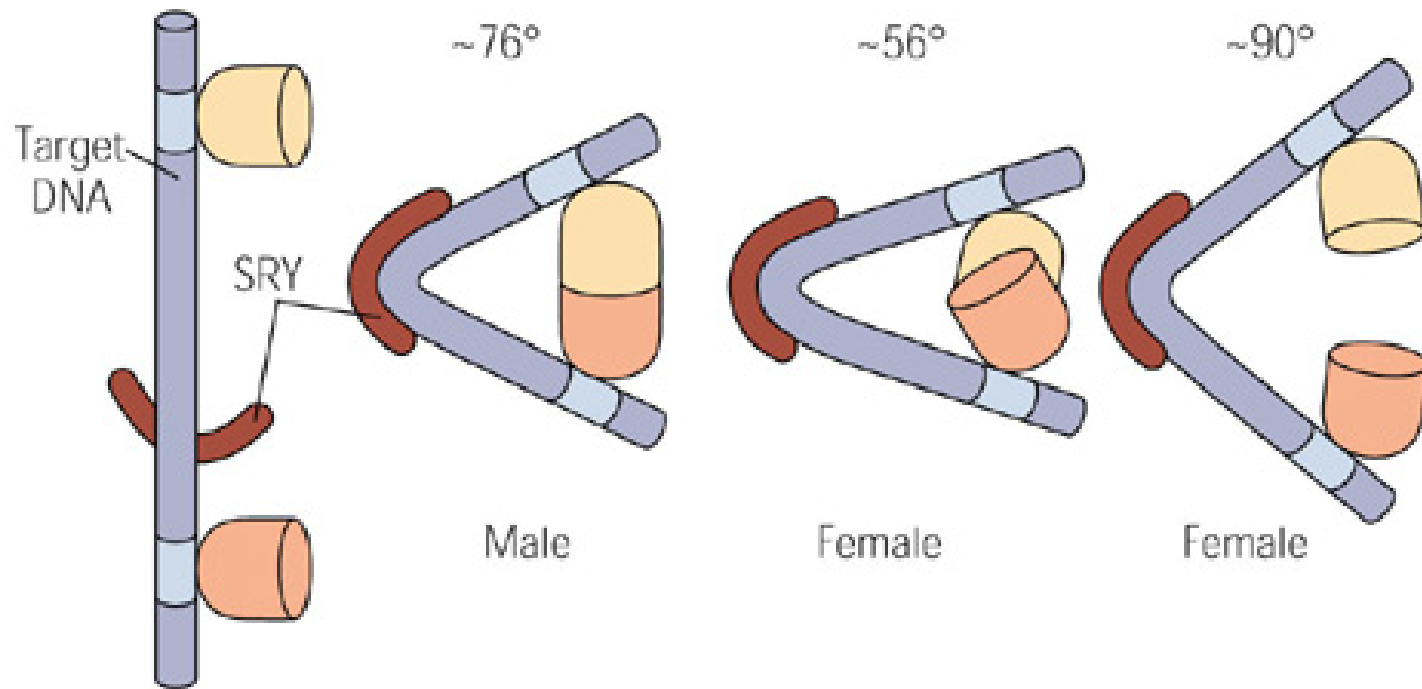
- Team decision
- Based upon all the facts
- Parental wishes
- Adult sexual function
  - The brain is the most important sex organ
- Reproductive capacity
- Gender identity
- Physical characteristics and potential for growth/function

Questions?

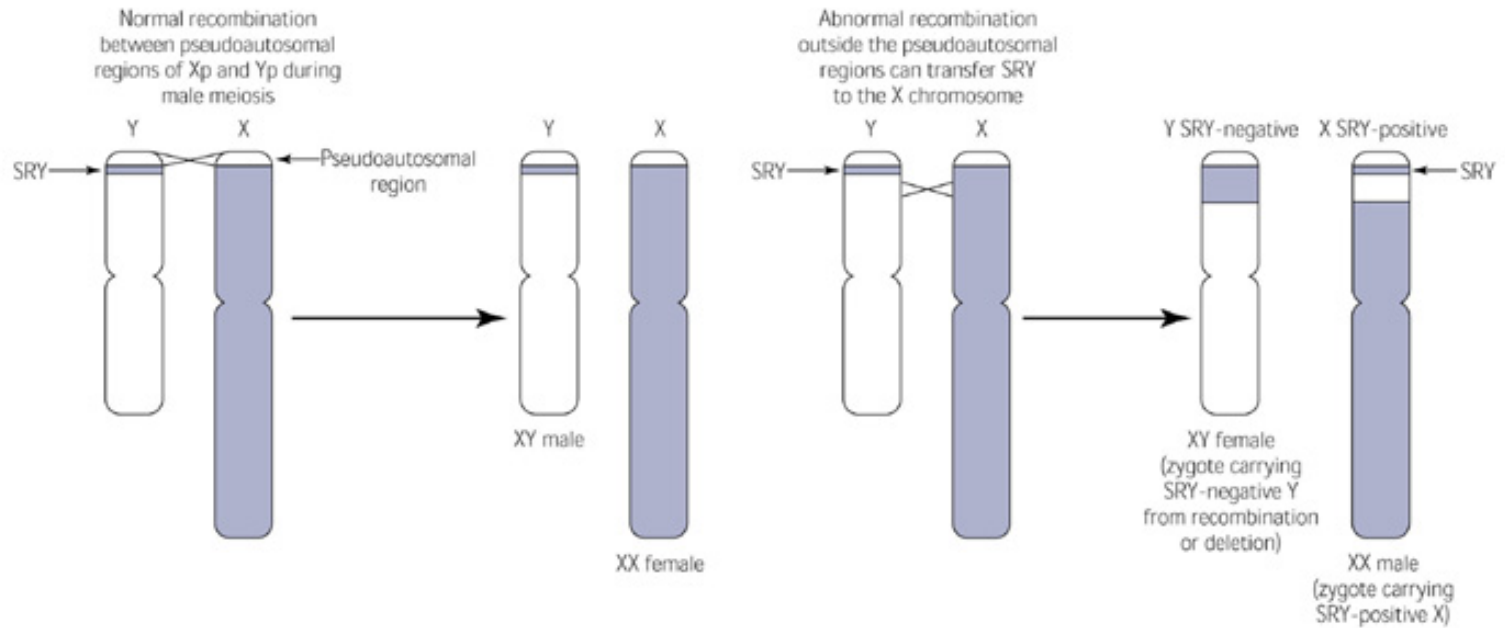




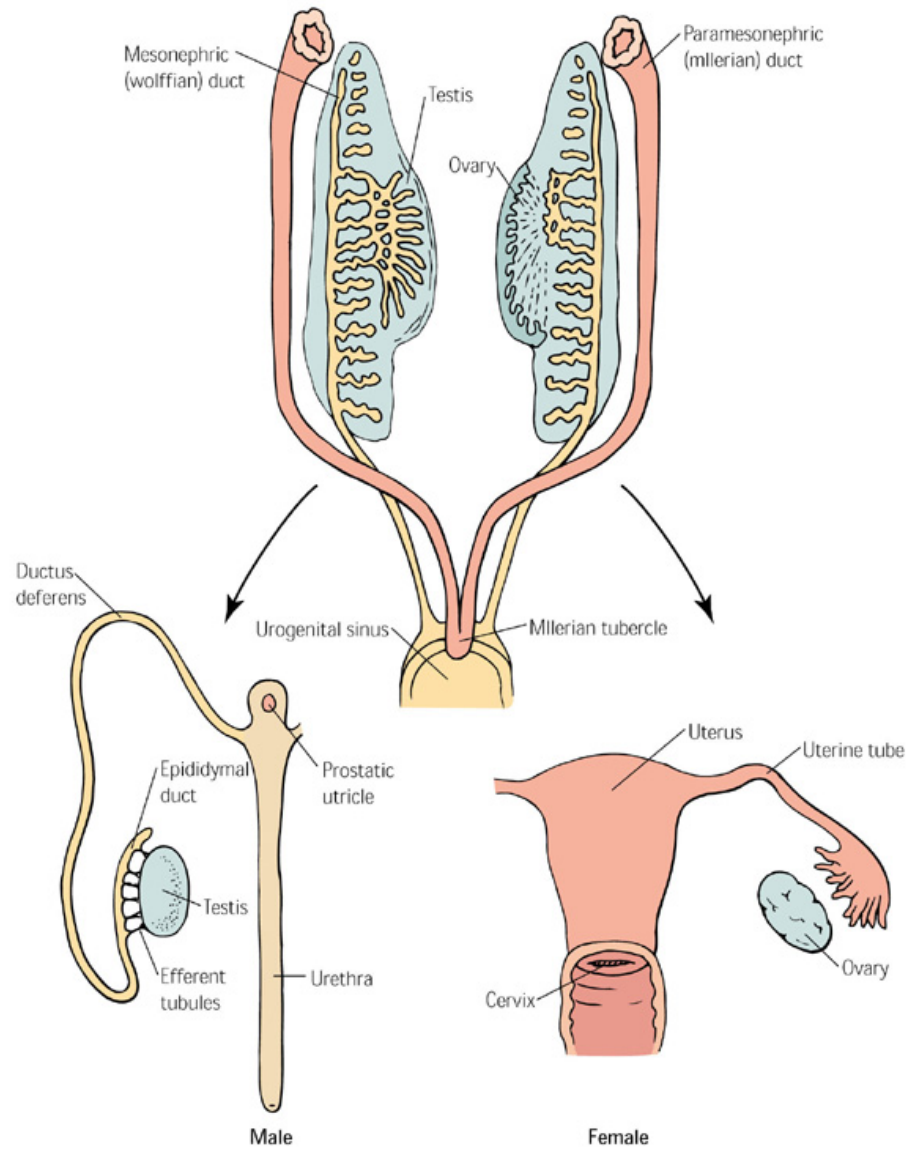
# Target DNA bending



# X-Y recombination during paternal meiosis



# Undifferentiated sexual system



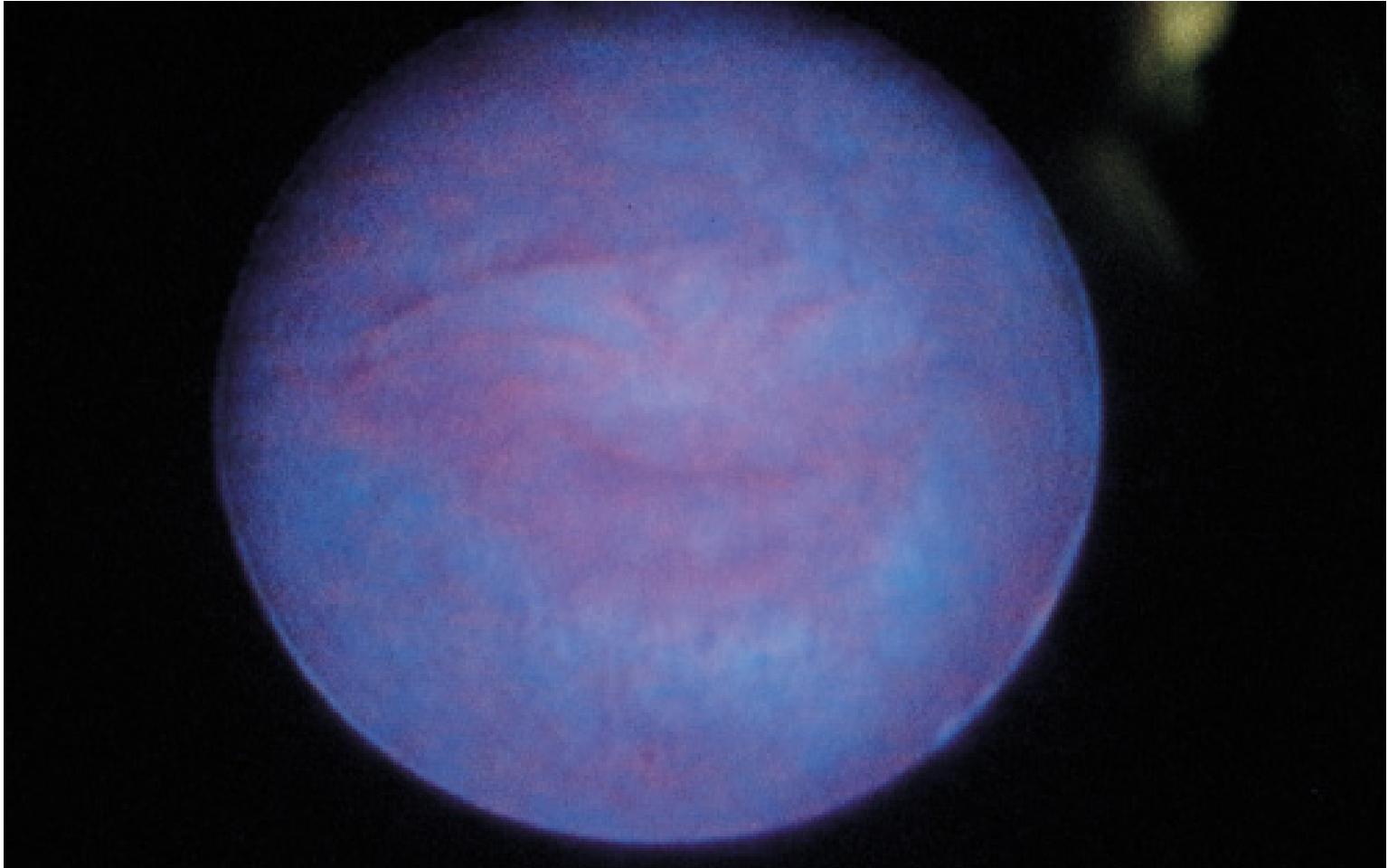
# Classifications for patients with abnormalities of sexual differentiation

## B. Two Classifications for Patients with Abnormalities of Sexual Differentiation

Original Classification	New Classification
Male pseudohermaphroditism	1. Deletion syndromes with Y cell lines (45,X/46,XY)
	2. 46,XY
	a. Gonadal dysgenesis (Swyer's syndrome)
	b. Empty pelvis: agonadia
	c. Enzyme deficiencies
	Enzyme deficiencies affecting both adrenals and testes (variants of CAH)
	—Cholesterol side-chain cleavage (P-450 <sub>scc</sub> ) deficiency
	—3 $\beta$ -hydroxysteroid dehydrogenase (3 $\beta$ -HSD) deficiency
	—17 $\alpha$ -hydroxylase (P-450 <sub>c17</sub> ) deficiency
	Enzyme defects primarily affecting the testes
	—P-450 <sub>c17</sub> hydroxylase/17,20-lyase deficiency
	—17 $\beta$ -hydroxysteroid dehydrogenase (17-HSD) or 17 $\beta$ -kerasteroid reductase deficiency
	5 $\alpha$ -reductase deficiency
	d. Androgen insensitivity or resistance
	Complete
	Incomplete
	e. Defects in synthesis, secretion, or response to AMH: persistent müllerian duct syndrome
	f. Nonendocrine/nonsex chromosome defects
	g. 46,XY true hermaphroditism
	3. 46,XX/46,XY true hermaphroditism
	4. 46,XX
True hermaphroditism	
Female pseudohermaphroditism	a. 46,XX true hermaphroditism
	b. 46,XX sex reversed male
	c. Congenital adrenal hyperplasia
	21-hydroxylase deficiency forms
	11 $\beta$ -hydroxylase deficiency
	3 $\beta$ -ol-dehydrogenase deficiency
	d. Aromatase (placental) deficiency
	e. Maternal androgen



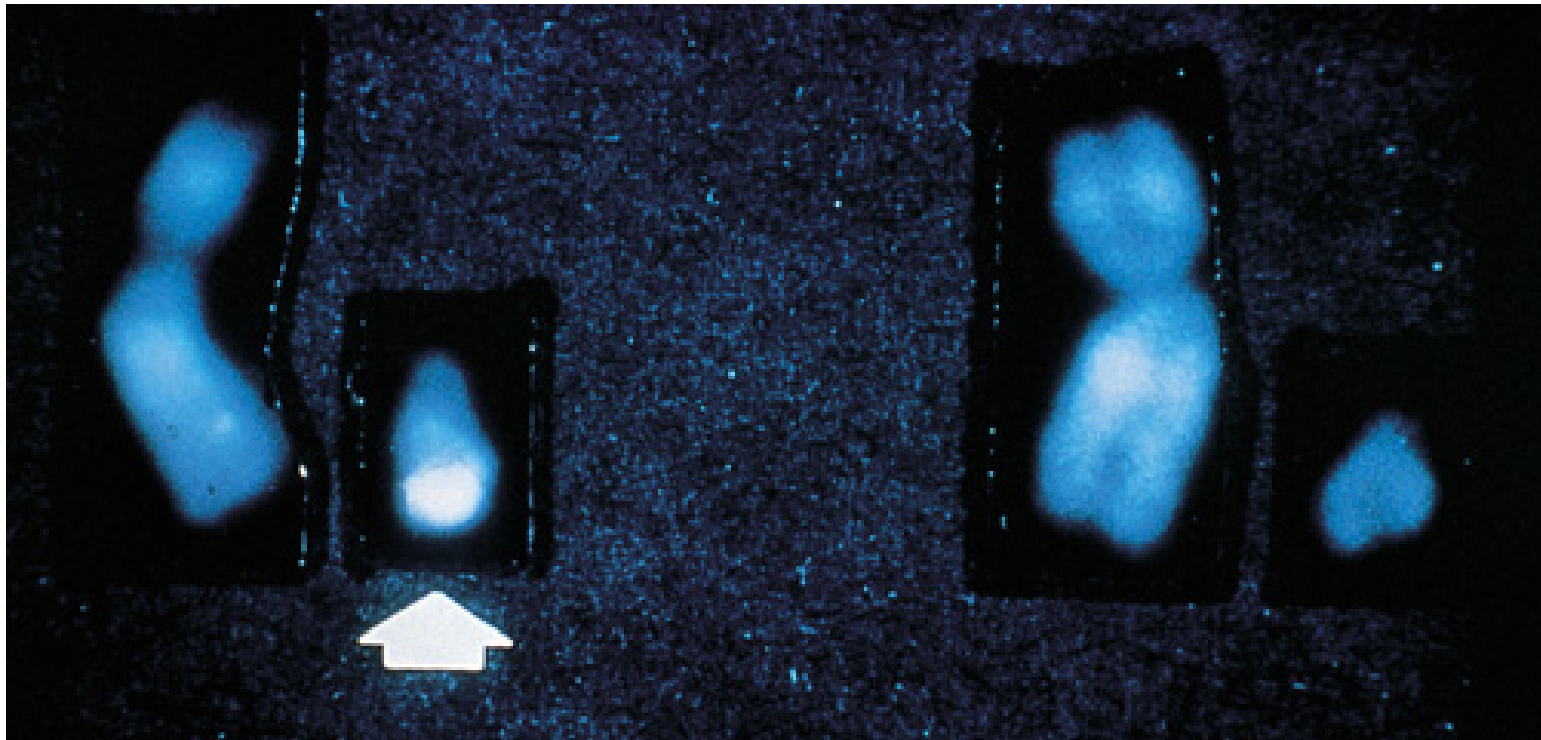
# Cervix



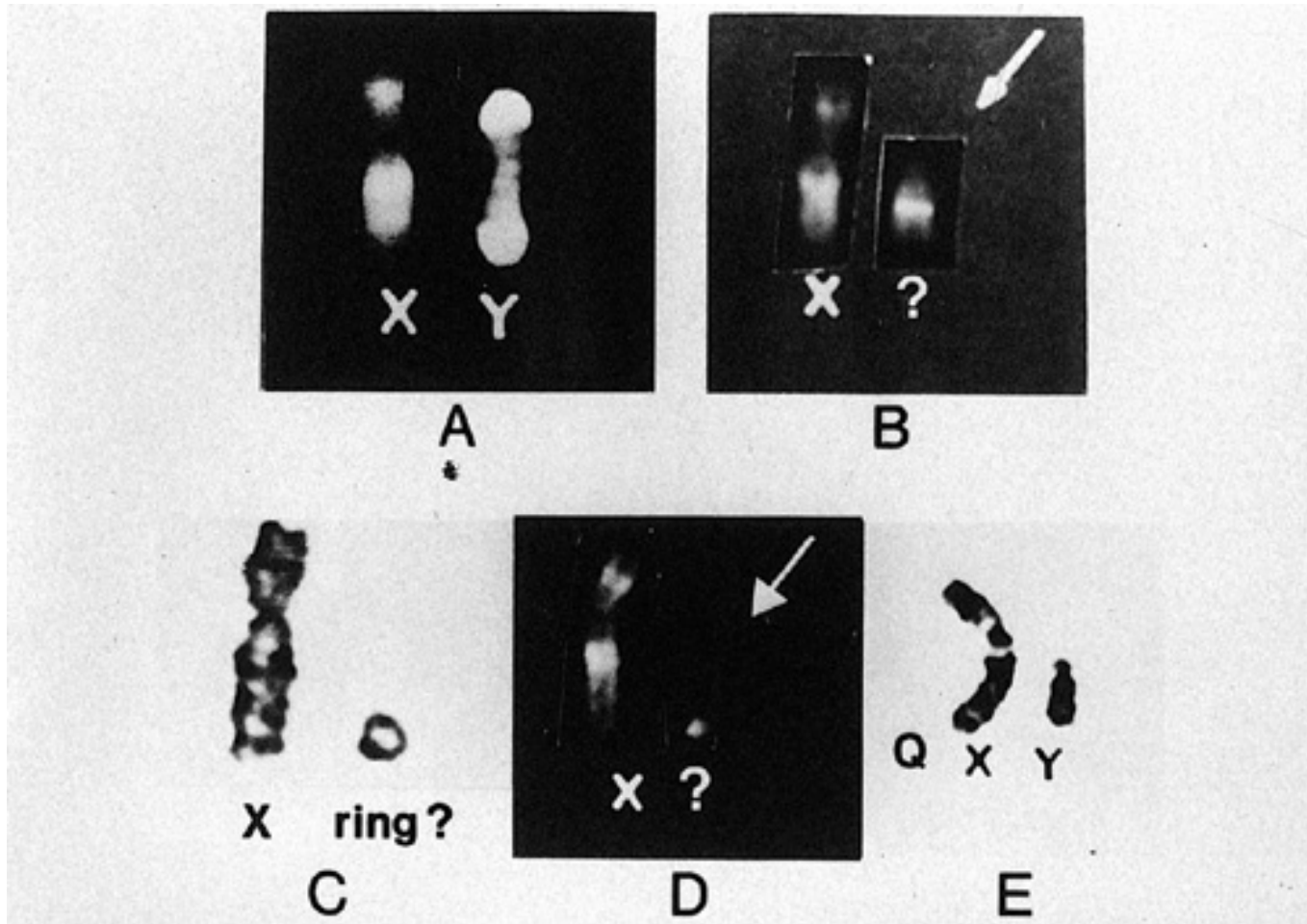




## Detection of Y chromosome by Q banding



# Y variants

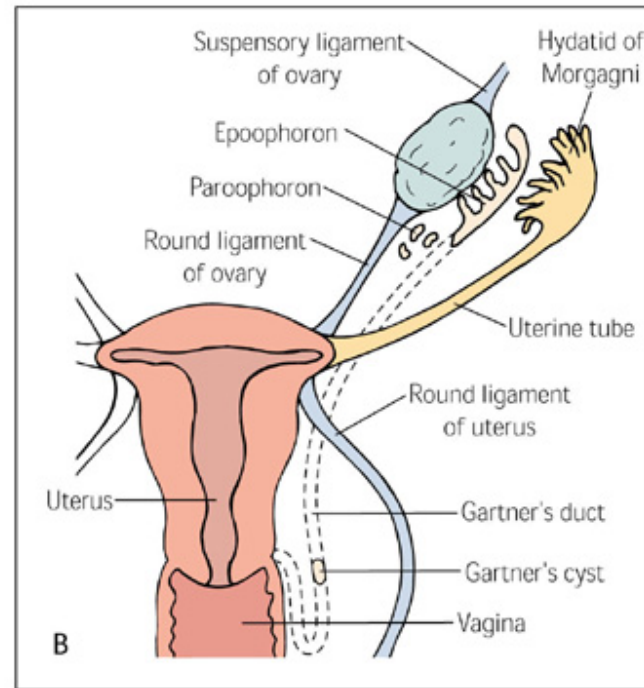
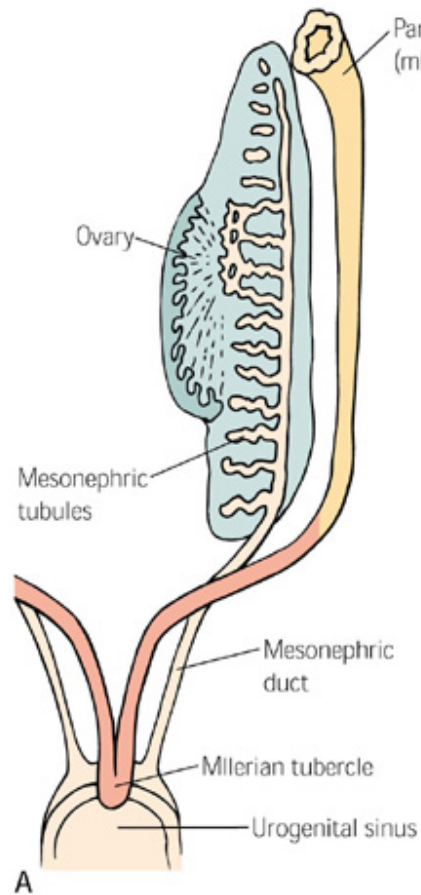




# Y DNA probes

Pseudoautosomal		Probe	Locus
	1	SRY, pDP1007(ZFY)	
Yp	2		
	3	pDP105A .....	DYZ 4A
	4A		
Ycen	4B	Y97 .....	DYZ 3
Yq11	5		
	6	pDp105B .....	DYZ 4B
		4B-2 .....	DYZ 15
Yq12	7	pS4 .....	DYZ 2

# Female genital duct system



# Molecular aspects of 21-hydroxylase (P-450<sub>c21</sub>) deficiency

## E. Molecular Aspects of 21-Hydroxylase Deficiency

Activate gene CYP21B and pseudogene CYP21A are located in tandem duplication on chromosome 6 and with 98% homology.

Each gene is 3.3 kb long and has 10 exons.

The two genes are flanked in tandem by the C<sub>4</sub>A and C<sub>4</sub>B genes which encode the fourth component of complement.

### Salt wasting form

1. Homozygous large deletion of CYP21B and C<sub>4</sub>B loci: 20% to 25% of classic form.
2. Homozygous large gene conversion resulting from transfer to CYP21B of deleterious mutations normally present in CYP21A pseudogene: 10%.
3. Compound heterozygous harboring, for example, a large deletion on one chromosome 6 and a large gene conversion or a nonsense mutation on the other chromosome 6.
4. The most frequent point mutation is the single base pair change from A to G at the end of intron 2 leading to premature truncation of intron 2 and an mRNA splicing defect preventing synthesis of an active protein.

### Single virilizing form

1. Mutation involving change from isoleucine to asparagine. This mutation weakens the association of the enzyme with the endoplasmic reticulum and results in reduction of enzyme activity to about 1% of normal.
2. The A to G point mutation in intron 2 is also associated with the simple virilizing form.

### Nonclassic form

1. Valine to leucine mutation at position 281 results in the abnormal localization of the mutant enzyme and in the microsome enzyme activity is reduced by 20% to 50% for the substrates progesterone and 17-OHP. Adequate aldosterone production along with excessive androgen lead to variable degrees of hirsutism or virilization.
2. Proline to leucine mutation at position 30 also leads to improper orientation of the enzyme in the membrane of the microsome. This mutation appears to be associated with more severe biochemical changes as well as androgen excess.

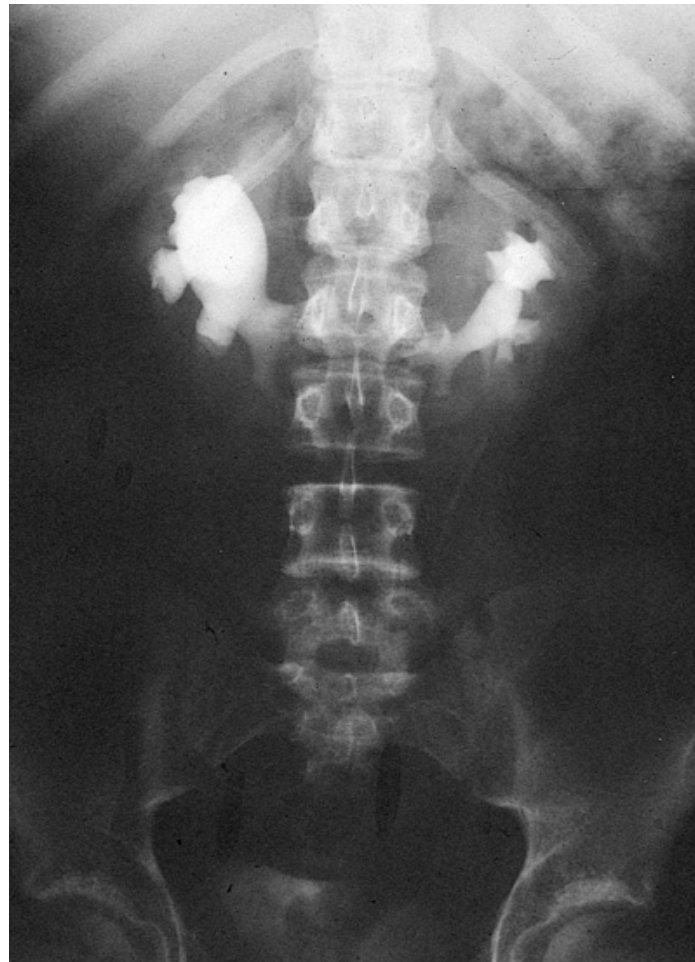# Basic features of 3β, -hydroxysteroid dehydrogenase deficiency

## D. Basic Features of 3β-HSD Deficiency

3β-HSD	Two forms of 3β-HSD Deficiency
Single protein with both dehydrogenase and isomerase activities, localized in the endoplasmic reticulum of the cells of the adrenal cortex, ovary, testis, and placenta.	1. Classic 3β-HSD deficiency with complete block of 3β-HSD activity leading to deficient production of glucocorticoids, mineralocorticoids and gonadal steroids.
Responsible for conversion of β <sup>5</sup> -3β-hydroxysteroids (pregnenolone, 17-hydroxypregnenolone, and DHEA) into β <sup>4</sup> -3β-ketosteroids (progesterone, 17-hydroxyprogesterone, and androstenedione).	Inability to produce cortisol results in: —Increased ACTH secretion and adrenal hyperplasia.
	—Males present with ambiguous genitalia owing to insufficient production of androgens.
Required for synthesis of cortisol, mineralocorticoids, and gonadal steroids.	—Glucocorticoid and mineralocorticoid deficiencies occur, resulting in adrenal insufficiency ? classification into 3β-HSD/salt wasting and 3β-HSD/salt conserving.
	2. Nonclassic 3β-HSD with partial block, late onset, no salt wasting, no genital ambiguity.



# Horseshoe kidney





# Basic features of P-450<sub>SCC</sub> (cholesterol side-chain cleavage) deficiency in 46,XY male

## B. Basic Features of P-450<sub>SCC</sub> (Cholesterol Side-Chain Cleavage) Deficiency in 46,XY Male

Cholesterol side-chain cleavage enzyme (P-450 <sub>SCC</sub> or 20, 22-desmolase) is a mitochondrial P-450 enzyme.
Catalyses the initial reaction in the steroidogenic pathway in the gonads and adrenals.
Cleaves a 6-carbon side-chain for cholesterol to form pregnenolone, a C <sub>21</sub> steroid.
This reaction is rate-limiting
Regulated by ACTH and angiotensin II in the adrenals
Regulated by gonadotropins in the gonads
In P-450 <sub>SCC</sub> deficiency, inability to metabolize cholesterol in the adrenals leads to cholesterol ester deposition resulting in enlarged, yellow, foamy adrenal glands: lipoid adrenal hyperplasia.



# Salient features of congenital lipoid adrenal hyperplasia

## C. Salient Features of P-450<sub>SCC</sub> (Cholesterol Side-Chain Cleavage) Deficiency in 46,XY Male: Congenital Lipoid Adrenal Hyperplasia

Karyotype:	46,XY
Inheritance:	Autosomal recessive
Genitalia:	Female ? ambiguous
Wolffian duct derivatives:	Absent ? hypoplastic
Müllerian duct derivatives:	Absent
Gonads:	Testes
Habitus:	Severe adrenal insufficiency in infancy, little or no virilization at puberty
Hormone profile:	? or absent glucocorticoids, mineralocorticoids, and gonadal steroids in plasma and urine ? plasma LH and FSH
Molecular genetics:	CYP11A <sub>1</sub> , single gene localized to chromosome 15q23-24, 9 exons, 8 introns
	No mutations found

# Salient features of 3β, -hydroxysteroid dehydrogenase deficiency in 46,XY males

## E. Salient Features of 3β-HSD Deficiency in 46,XY Males

Karyotype:	46,XY
Inheritance:	Autosomal recessive
Genitalia:	Almost normal female to male with degrees of hypospadias
Wolffian duct derivatives:	Normal
Müllerian duct derivatives:	Absent
Gonads:	Testes
Habitus:	Severe adrenal insufficiency in infancy; poor virilization at puberty with gynecomastia. Mild form: no mineralocorticoid deficiency, premature adrenarch ? mild virilization
Hormone profile:	? concentrations of $\delta^5$ C <sub>21</sub> and C <sub>19</sub> steroids (eg, 17-hydroxypregnenolone, DHEA, and their sulfates) in urine and plasma
	? ratio of $\delta^5/\delta^4$ steroids
	? 17-hydroxypregnenolone and DHEA response to ACTH and/or hCG
Molecular genetics:	17-hydroxypregnenolone and DHEA suppressible by dexamethasone
	Two isoenzymes 3β-HSD type I and type II
	Type I expressed in placenta and skin
	Type II expressed in adrenal, ovary, and testis
	Genes: localized to chromosome 1q11-13, with 93% homology
	Mutation reported in fourth exon of type II gene, codon 171 converting tryptophan to stop codon leading to formation of a truncated nonfunctional enzyme



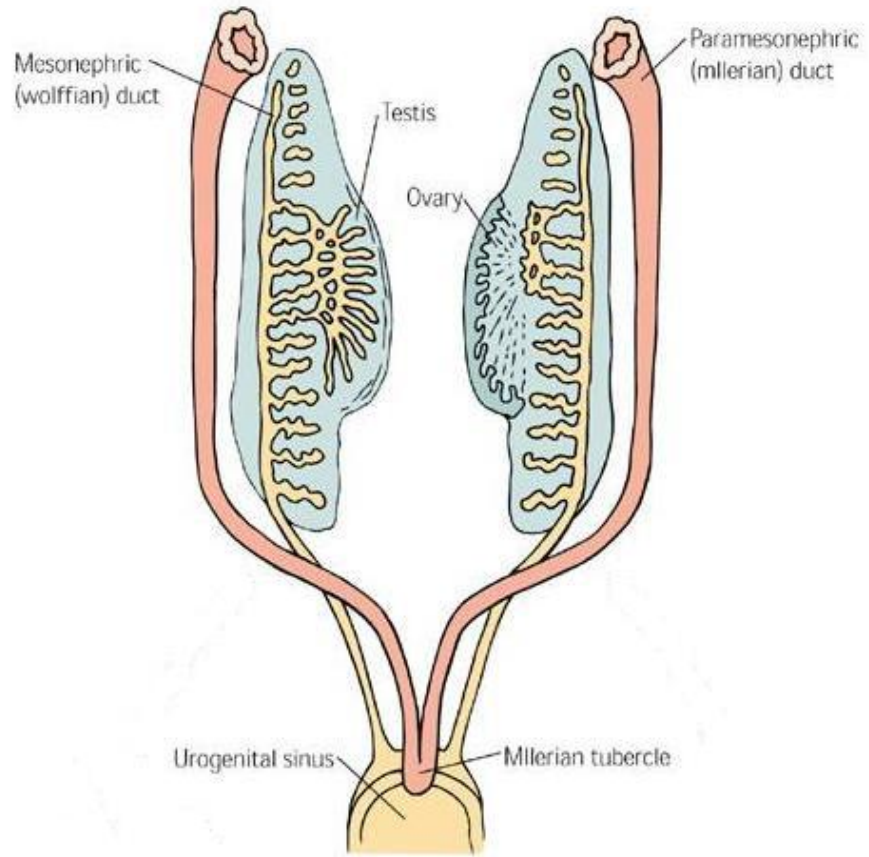
# Features of androgen resistance or insensitivity

## B. Basic Features of Androgen Resistance or Androgen Insensitivity

Testosterone and its reduced metabolite DHT effect their action in androgen-sensitive target cells by binding to androgen receptor.

Androgen receptor is a member of a family of regulatory proteins which include all steroid receptors, and receptor for thyroid hormone, vitamin D, and retinoic acid. These receptors contain (1) NH<sub>2</sub>-terminal region involved in transcription activation; (2) cysteine-rich DNA binding with two zinc fingers that bind to specific androgen response elements in target genes and; (3) COOH-terminal ligand binding domain for testosterone and DHT.

Androgen response may be completely or partially blocked in 46,XY males, resulting in absent or partial development of Wolffian ducts and absent or partial development of male external genitalia during fetal development. Because testes produce AMH, müllerian ducts regress leading to absent female internal genital structures.



# Androgen resistance

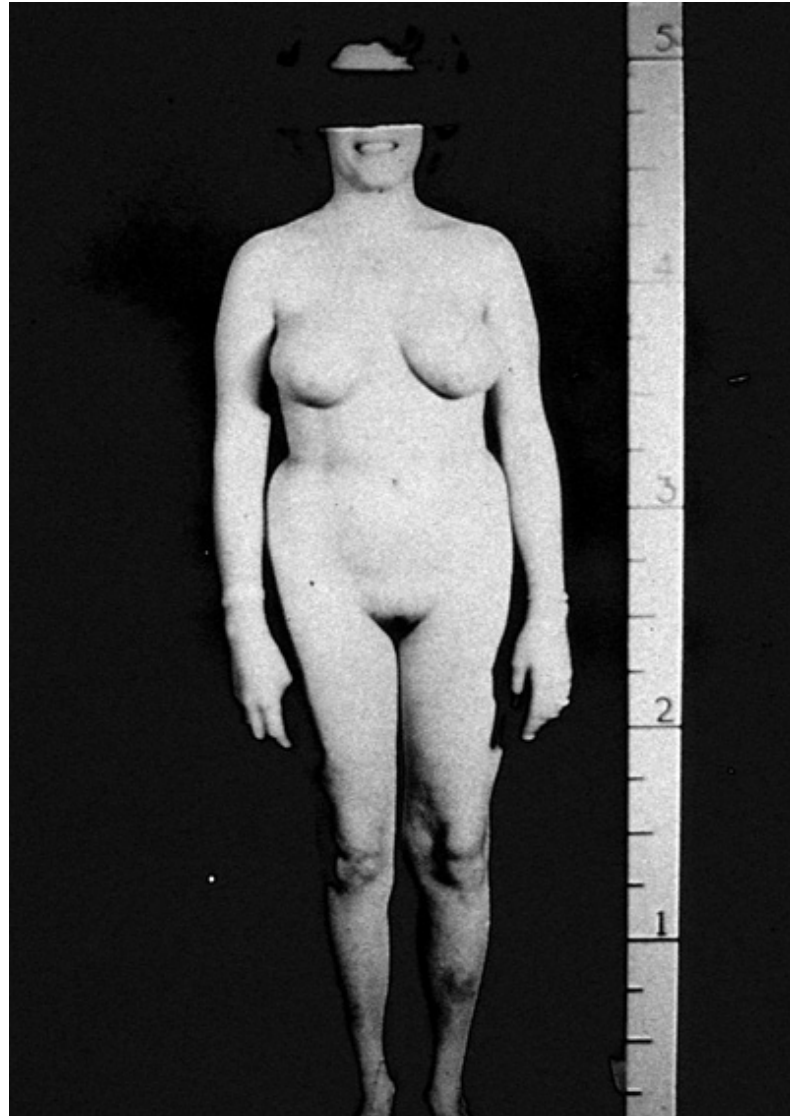
**18y old “female”**

**Tanner IV breast**

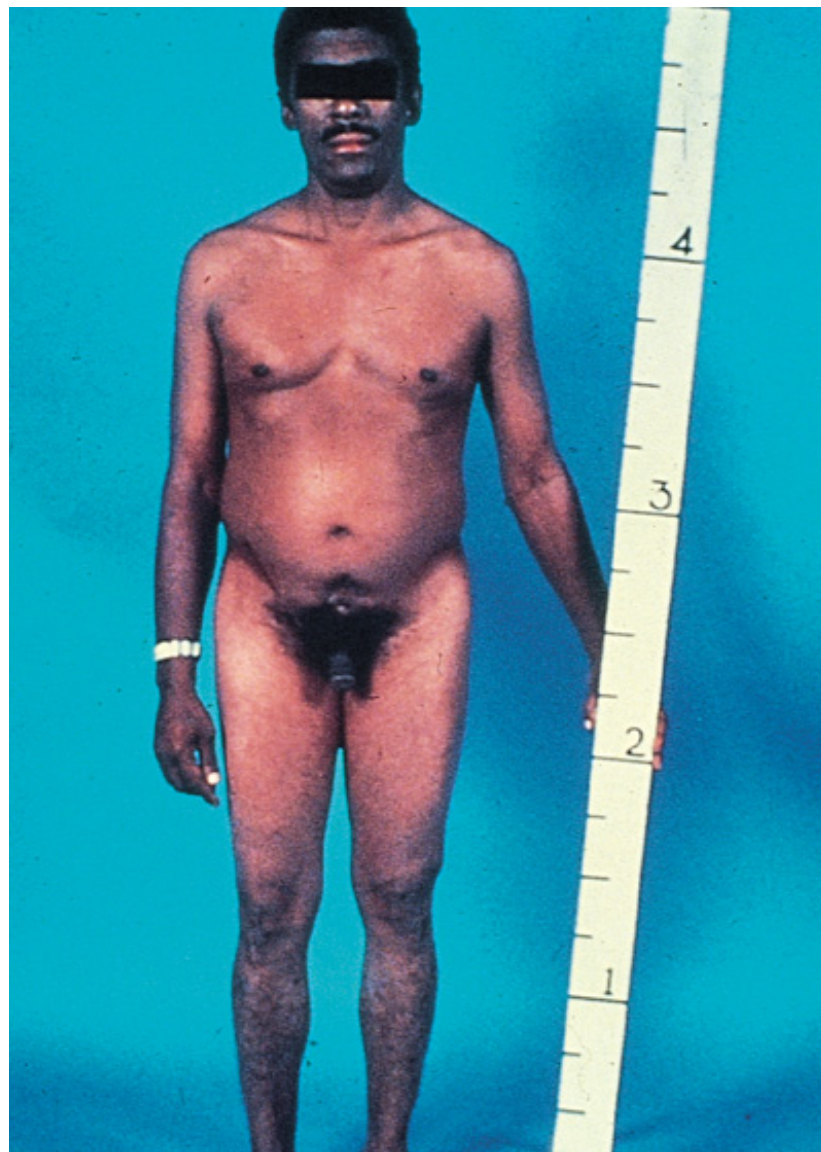**Absent Pubic hair**

**Blind vagina**

**46,XY**



**46,XX “sex-reversed male”**



# 46,XX karyotype reversed male

## B. 46,XX Sex Reversed Male

Karyotype:	46,XX
Inheritance:	Sporadic
	Rare kindred including both XX males and XX true hermaphrodites
Genitalia:	Male
	Hypospadias (10%)
Wolffian duct derivatives:	Normal
Müllerian duct derivatives:	Absent
Gonads:	Testes
Habitus:	Normal male, slightly shorter than normal males. Few develop gynecomastia at puberty, owing to hypogonadism; those born with hypospadias tend to develop gynecomastia at puberty. All have azoospermia.
Hormone profile:	Testosterone normal or decreased FSH; LH normal or low
Molecular genetics:	90% result from transfer of SRY from Y to X during paternal meiosis 10% result from mutation of X-linked or autosomal genes involved in gonadal determination